

# REPORTS OF MORPHOLOGY

## 2013 – VOL.19, №1

### ORIGINAL ARTICLES

© Chaikovsky Yu.B.<sup>1</sup>, Yatsenko V.P.<sup>2</sup>, Yatsenko E.V.<sup>2</sup>

<sup>1</sup>O.O.Bogomolets National Medical University, Chair of histology and embryology (Peremohy avenue, 34, Kyiv, Ukraine, 03056, [yuchaiko@i.ua](mailto:yuchaiko@i.ua); <sup>2</sup>National Technical University of Ukraine “Kyiv Polytechnic Institute”, Intercollegiate Faculty of Medical Engineering, Department of Medical Cybernetics and Telemedicine, Peremohy avenue,37, Kyiv, Ukraine, 03056, [valentinyatsenko@ukr.net](mailto:valentinyatsenko@ukr.net)

### HISTO-EMBRYOGENETIC AND INFORMATIONAL ASPECTS OF ERYTHRON DEFINITIVE COMPONENT NOTION IN ESTIMATION OF ERYTHROCYTES DEFORMABILITY PECULIARITIES (REPORT 1)

**Introduction.** Over the last 30 years in domestic and foreign papers numerous studies have been published on the ability of erythrocytes to alter their surface architecture, shape and size. This process has got the name of deformability. It was established that the general pattern of this process in the form of preferential deformation consists of two subtypes of red blood cells - echinocytes and stomatocytes. The evidence of possible transformation of echinocytes into stomatocytes or vice versa has not been presented.

The aim of this study was to find theoretically and practically important approaches to system analysis of echinocyte-stomatocyte transformation of definitive erythron components in assessing of erythrocyte deformability in human peripheral blood.

**Materials and methods.** To estimate erythrocytes transformation index (EVI) erythrocytes were divided in 15 varieties (normocyte-a, echinocyte<sub>1</sub> - b1, echinocyte<sub>2</sub> - b1, stomatocyte<sub>1</sub> - b2, stomatocyte<sub>2</sub> - b2, stomatocyte<sub>3</sub> - b2, targetlooking<sub>1</sub> - b2, elliptocyte - b3, echinocyte<sub>3</sub> - c, echinocyte<sub>4</sub> - c, stomatocyte<sub>4</sub> - c, spherocyte - c, targetlooking<sub>2</sub> - d, sicklelooking or drepanocyte - d, deformed or acanthocyte - d). Five levels of changes were identified: standard (EVI <0.5), small changes (0.5 <PME <1.5), moderate changes (1.5 <PME <2.5), pronounced changes (2.5 <PME <5.0) and severe changes (PME >5.0).

We calculated erythrocytes transformation index (ETI) according to the following algorithm:

$$ETI = \frac{RD + ID}{D}$$

where: D - % of normocytes; RD - % of reversibly transformed erythrocytes; ID - % of irreversibly transformed erythrocytes.

Studies were conducted on the peacekeeping force (40 men) who served in Kosovo. Statistical processing was carried out by t-test.

**Results.** Two information indices (EVI and ETI) estimated in three subgroups of healthy men, carrying out a peacekeeping mission, revealed certain patterns that could be reliably characterized by dynamic changes in the components of the definitive deformability of erythron. The data presented in Table 1 show that the regular increase in EVI was accompanied by increase of the total value of ETI and its constituents (reversible and irreversible transformation) and decrease of normocytes quantity.

**Table 1.** Dynamics of EVI and ETI changes in studied groups of observations.

Group	ETI	RD, %	ID, %	D, %
1 group (EVI 0.04-0.14)	0.020	1.42	0.51	98.10

Thus, our findings largely confirm the assumption that echinocytes and stomatocytes are varieties of specific differentiation of red blood cells and make up the components of the definitive erythron.

**Conclusion.** Theoretical view about echinocytes and stomatocytes as varieties of specialized red blood cell differentiation has been defined for the first time from the histo-embryogenetic standpoint.

Morphometric comparative analysis of erythrocytes volatility index (EVI) and of erythrocytes transformation index (ETI) showed them to indicate changes in the "echinocytes - stomatocytes" system.

Elaborated methodical approach can be recommended as an easy to perform method for general clinical and research institutions of different areas of morphology, physiology, experimental and clinical medicine, sports, aviation and space medicine.

**Key words:** erythrocyte deformability, echinocytes, stomatocytes, morphometry, the entire organism, reactivity, adaptation, statistical analysis.

© Popel S.L.

Ivano-Frankivsk, Ukraine

## **STRUCTURE OF MICROCIRCULATORY NETWORK OF SEPARATE ELEMENTS SIMPLE REFLEX ARC AT LIMITATION OF MOTIVE ACTIVITY**

**Introduction.** In modern terms increases dramatically attention of scientists of various disciplines to the impact on the human limitation of motor activity or hypokinesia. Its development is due to the pace of mechanization and automation of manufacturing processes, leading to an increase in the percentage of trades mental and physical work light. Of special urgency is the issue due to prolonged stay in a state of hypokinesia and physical inactivity during space flight. Hypokinesia is also an important component of many clinical diseases that result from forced bed regime and accompanied by prolonged immobilization of limbs or whole body.

At the present stage of morphological science gained sufficient experience on the effect of hypokinesia on water and electrolyte balance in the body, the restructuring

of bones, lymph nodes and spleen, a number of internal organs (kidney, heart, lung, liver). There are no data on changes in the vascular wall insight arising during hypokinesia. *Purpose* - to examine morphological changes mikrohemosudyn components of a simple reflex arc during hypokinesia.

**Material and methods.** Studies conducted on laboratory mature male rats (total 250 animals) under legal and regulatory provisions. Limited physical activity in individual cells-case. Injected, no injection and electron microscopic techniques and a method of combined detection of nerve cells and blood vessels. Statistical analysis of the results was performed using the software package "Statistisa 5".

**Results.** Area capillary channel depends on the size of the nerve cells. Around the major highlight of neurons is an average of  $1433,5 \pm 19,61 \text{ um}^2$  and around small dark - only  $836,0 \pm 10,22 \text{ um}^2$ .

In the experiment on white not thoroughbred rats the morphological changes in the separate component components of simple reflex arc in different terms after the design of long duration hypokinesia are studied. It is set that hypokinesia shows up the appropriate dynamics of histo-ultrastruction changes of cellular elements in composition a simple reflex arc, which correlate with undulating phases increases and stabilizations of permeability of vascular wall for the marker of transendotelial transport. Findings well conform to information which got other researchers and is confirmed statistically by reliable quantitative indexes.

**Conclusins.** 1. Ultrastructural structure of the capillary-hlio-neuronal systems in mature rats ensures the stability of neuronal blood-barrier. All structural components of a simple reflex arc leading role in the creation of barrier function belongs ultrastructural structure hemokapilyariv as dense mizhendoteliotsytnyh contacts, three-layer continuous basement membrane and glial environment. 2. Restructuring of the constituent elements of a simple reflex arc during hypokinesia characterized by a decrease in the total number of blood vessels and the impoverishment of its own capillary bed each neuron, their processes and nerve endings. Such changes underlying ischemia constructs a simple reflex arc and degenerative phenomena in the neuron-glia complexes. 3. The destruction of the structural components of neuronal blood-barrier (no tight mizhendoteliotsytnyh contact separation of basal membranes, loss of neuron-glia close and hlio-capillary contacts) during hypokinesia leads to increased destructive processes throughout nervovoprovidnykovomu complex simple reflex arc.

**Key words:** hypokinesia, simple reflex arc, vascular permeability, colloid gold.

© **Komshuk T.S., Pishak V.P.**

Chernivtsi, Ukraine

**MORPHOMETRIC FEATURES CAPILLARY LOOPS OF THE VILLI OF THE CHOROID PLEXUS OF THE FOURTH VENTRICLE THIRD AND**

## HUMAN BRAIN IN THE AGE ASPECT

**Introduction.** Vascular plexus of the human brain is the main source of cerebrospinal fluid that carries out such important functions as maintaining the sustainability of intracranial pressure, mechanical and immunobiological protection brain, its metabolism and transport to the brain biologically active substances.

Objective: to study morphometric features of capillary loops villous vascular plexus of the third and fourth ventricles of the human brain in terms of age.

**Materials and methods.** Performed morphometric studies of the capillary loops of the villi of the vascular plexus of the third and fourth ventricles of the brain in 42 people aged 22 to 90 years. The study used methods of preparing thin brain controlled binocular loupes; macro- and microscopic. material fixed in cold acetone and embedded in paraffin. From the paraffin blocks were made serial sections of thickness 10 microns. Functionally active capillary bed villous vascular plexus detected using histochemical reaction for alkaline phosphatase by Burstone (1962) in the modification Lloyd et al (1982). The length of the capillary vascular plexus of fibers was determined using a micrometer CMOS color digital camera for microscopes "T 100 SCIENLAB 10,0 MRix." The evaluation of the statistical significance of the data was performed by Student t-test.

**Results.** Ventricular system - is connected to the central canal of the spinal cord and subarachnoid space anastomosing system of cavities containing cerebrospinal fluid and glial cells on the apical surface. In some areas ependymotsyty have specific structural and functional features and are involved in the production of cerebrospinal fluid and chemical "alarms". The production of 70-90% of cerebrospinal fluid provide vascular plexus of the ventricles of the brain - in the roof structure III and IV ventricles, and the walls of the lateral ventricles.

All typed material was divided in 4 age groups: mature age, I period (22-35 years men and women 21-35 years); mature age, II period (36-60 men and women 35-55 years); elderly (61-74 years 56-74 years men and women); old age (75-90 years).

Age length of capillary villous vascular plexus of the third and fourth ventricles of the brain gradually decreases. The coefficient of correlation  $r$  takes the value from -0.69 to -0.93 ( $p < 0.01$ ).

**Conclusions.** Found that the most pronounced decrease in the length of the villi capillary vascular plexus of the third and fourth ventricles occurs in old age (at 23,16-26,42% relative performance period I matured, 19,60-21,39% compared to figures II period of mature of age). Significantly reduced the value of this parameter from the of elderly age category (56-74 years).

In vascular plexus fibers of the third and fourth ventricles of the human brain during aging changes occur unidirectional nature of the reduction that directly contribute to and lead to reduced production of cerebrospinal fluid, accompanied by adaptive transformations.

In vascular plexus epithelium of villi in the process of aging destructive changes occur that lead to degeneration of the formation of unstructured proteins and limestone deposits in the stroma vascular plexus, which in turn contributes function abnormalities hematolikvornoho barrier.

**Key words:** morphometry, villi vascular plexus of the brain ventricles, human.

© Havryliuk-Skyba H.O., Volkov K.S., Nebesna Z.M.

State Higher Educational Establishment «Ternopil I.Y. Horbachevsky State Medical University», Ternopil

## **ELECTRON MICROSCOPIC STATE OF STRUCTURAL COMPONENTS OF THE SPLEEN IN LATE PERIODS AFTER EXPERIMENTAL THERMAL INJURY**

**Introduction.** In mature white male rats there has been conducted submicroscopic research of the spleen in late periods after experimental thermal injury. It has been defined that on the 14 and 21 days after the burn deep destructive changes occur of all structural components of the white and red pulps of the spleen.

The work is a part of the SRW «Usage of the factors of bioorganic and physical nature to correct regenerative processes during heat injury», № state registration 0109U0002901.

The immune system reacts to pathological factors of various origins. However, there are not enough researches in the scientific literature concerning ultrastructural status of structural components of the spleen in thermal injury of skin. This is due to a small number of submicroscopic studies of peripheral immune organs, especially burns, what complicates understanding of the development of an effective immune response and immunomodulation processes that occur at the same time.

*The aim* of the work was the establishment of the characteristics of submicroscopic changes in the structural components of the spleen in the late periods after experimental burn injury.

**Materials and methods.** The experiment was conducted on 20 mature white male rats. Animals were kept in a vivarium with the requirements of bioethics.

A burn was applied under ketamine anesthesia with copper plates heated in boiling water. The area of damage was 18-20 % of animals' body surface, the burn was of the third degree. The animals were decapitated at 14 and 21 days of the experiment (which corresponds to the late stages of toxemia and septicotoxemia burn disease). Collection of material and processing pieces of spleen for submicroscopic investigation were performed according to conventional methods [6]. Ultrathin sections were made on ultramicrotome LKB-3, contrasted and studied in the electron microscope TEM-125K.

**Results and discussion.** Previously conducted histological examinations of the spleen of animals in the early stages (1, 7 days) after thermal injury have established the development of adaptive-compensatory and initial signs of destructive changes in the structure of the spleen.

Submicroscopic researches of the spleen at the 14 day (stage of late toxemia) have shown growth of destructive changes of these structural components in comparison with the early stages of the experiment. In the loops of reticular network of red pulp

cords there have been observed significantly damaged red blood cells with altered shape and high osmophilic of their internal contents. There have also been noticed lymphocytes of different maturity are presents. The number of plasma cells and active phagocytes macrophages decreases in comparison with the early stages of the experiment. Macrophages are increased in size with cell membrane invaginations and large cytoplasm protrusions. There are many autophagosome and phagocytized fragments of erythrocytes in their cytoplasm. There are also damaged macrophages, with small bodies, osmophilic cytoplasm and karyoplasm, nuclei is pyknotic (fig. 1). In the cytoplasm of plasma cells occurs deformation and expansion of granular endoplasmic reticulum (GER), cisternae of Golgi complex and destruction of mitochondria. The nuclei of plasma cells have irregular shape, a lot of invaginations of nuclear envelope and are located eccentrically. In reticular cells there are also observed altered irregularly shaped nuclei with invaginations of nuclear envelope. They are characterized by electron dense cytoplasm, thin processes and damaged organelles: mitochondria with enlightened matrix and partially destroyed cristae. Located between pulp cords sinusoidal blood capillaries are expanded and plethoric with the development of sludge-phenomenon. In their lumen there have been observed damaged red blood cells with altered shape and high osmophilia of their internal contents. Filled with blood, capillaries are badly differentiated because their wall is damaged; cytoplasm areas and endothelial basement membrane are destroyed. Endothelial cells become flat, have extended or picnotic modified nuclear with osmophilic chromatin. There is lost a clear distinction between the vessel wall and contents of red pulp, and as a consequence, the appearance of hemorrhage in the red pulp.

Electron microscope examination of the spleen white pulp during this period of the experiment has shown that, in comparison with the early period after thermal injury the structure of reactive centers of lymphoblasts and lymphocytes in all areas of lymphoid nodules reasonably changes.

In periarterial zone there have been noticed mainly small and medium-sized lymphocytes and red blood cells. Lymphocytes nuclei are elongated, their nuclear envelope has invaginations, and in the cytoplasm there are a small number of organelles. Granular endoplasmic reticulum consists of short extended tubules, mitochondria with damaged cristae and enlightened matrix. Single cells with mitotic division are present.

In germinal center there are groups of small, medium lymphocytes and lymphoblasts around the dendritic cells. Single lymphoblasts have signs of mitosis while the others have destruction of nuclei and organelles in the cytoplasm. Lymphocyte nuclei have irregular shape and swelling cytoplasm with poor light and organelles. Beginning from this term of the experiment there has been marked the emergence of single erythrocytes of modified form. Dendritic cells have dense nuclei with invaginations of nuclear envelope, increased osmophilic cytoplasm and thin processes. The cytoplasm include of damaged organelles: fragmented short tubules of endoplasmic reticulum, underdeveloped Golgi complex and single mitochondria from the destruction of cristae (fig. 2).

Dark lymphocytes with deformed, irregularly shaped bodies appear in the mantial zone of the lymphatic follicle, with numerous invaginations and protrusions of plasmalemma. It has small nuclei with invaginations of nuclear envelope, their karyoplasm is osmophilic, there are many areas of heterochromatin. In some lymphocytes there have been observed micronuclei, typical for apoptosis.

There has been observed appearance of red blood cells with changed shape and high osmophilia of their internal environment in the marginal zone. Besides, the number of damaged plasma cells increases. Their deformed nuclei are located eccentrically. Expansion and fragmentation of tubules of granular endoplasmic reticulum, cisternae of Golgi complex and mitochondrial damage occurs in the cytoplasm (fig. 3).

Submicroscopic research on the 21 day of the experiment have shown significant changes in all structural components of the spleen. At the stage of septicotoxemia of burn disease in the loops of reticular network of red pulp cords there have been observed few plasma cells and active macrophages, and a large number of significantly damaged red blood cells with altered shape and high osmophilia of their internal content. Most macrophages are small and damaged, with increased electron density of the cytoplasm and karyoplasm, nuclei are pyknotic (fig. 4). Isolated active macrophages have the invaginations of plasmalemma, cytoplasmic protrusions, autophagosomes and phagocytized fragments of red blood cells (hemosiderin cells). The nuclei of plasma cells are irregularly shaped due to invaginations of nuclear envelope. Deformation and fragmentation of tubules of granular endoplasmic reticulum and cisternae of Golgi complex are revealed in their cytoplasm. The destruction not only of cristae but also of the outer membrane occurs in several mitochondria.

Reticular cells have dense bodies, thin processes, electron dense cytoplasm and damaged organelles. Their irregularly shaped nuclei are changed due to invaginations of nuclear envelope.

The blood capillaries in the red pulp with wide lumens are filled with blood, and their walls are rather damaged and poorly defined. Cytoplasmic areas of endothelial cells and basement membrane are partially destroyed. There has also been lost distinction between blood capillary wall and red pulp.

There has significantly been changed the structure of lymphoblast germinal centers and the lymphocytes of other areas of lymphoid nodules of white pulp. The density of small and medium lymphocytes is low in periarterial areas, the number of damaged red blood cells is increased, if compared with late stage of toxemia. Irregularly shaped lymphocytes nuclei are with deep invaginations of nuclear envelope, there are small numbers of damaged organelles in the cytoplasm. Cells with mitotic divisions are rarely seen.

In germinal centers amount of cells decreases. There appears hemorrhage and numerous diffusely located erythrocytes. Lymphoblasts with signs of mitosis are rare, while in others there is a profound degradation of nuclei and organelles. The nuclei of small and medium-sized lymphocytes have altered nuclei and cytoplasm is enlightened and poor with organelles. Dendritic cells have pyknotically changed nuclei with significant invaginations of nuclear envelope, and their electron dense cytoplasm has significantly damaged organelles.

In the mantial zone there has been observed destruction of numerous lymphocytes, which have profound changes of nuclei and organelles. There is fragmentation of tubules of granular endoplasmic reticulum, the enlightenment of matrix and destructions of membranes of mitochondria. The distinction between mantial zone and germinal center is lost.

**Conclusions.** In the marginal zone there is significantly reduced density of small and medium-sized lymphocytes, plasma cells, while there is a large number of damaged red blood cells and macrophages. The nuclei of some plasma cells have irregular shape, their cytoplasm is characterized by fragmentation of granular endoplasmic reticulum and mitochondria membranes destruction. Macrophages are small, have increased electron density of cytoplasm and damaged organelles; their nuclei are pyknotically changed with significant invaginations of nuclear envelope.

These research results are necessary for further study of the structural components of the spleen in situation of corrective factors application in heat injury.

**Key words:** spleen, electron microscopic changes, thermal injury.

© **Bodyaka V.Yu.**

Bukovinian State Medical University (Chernivtsi)

## **IMPACT OF ABDOMINAL HYPERTENSION ON PATHOMORPHOLOGICAL CHANGES OF ANIMAL INTERNAL ORGANS AFTER SIMULATION AND SURGICAL TREATMENT OF ACUTE INTESTINAL OBSTRUCTION**

**Introduction.** Despite considerable achievements of modern surgery acute intestinal obstruction continues to remain a serious illness which is accompanied by frequent development of complications in the early postoperative period.

One of the main factors of these complications are intra-abdominal hypertension, which occurs almost in every second patient with acute intestinal obstruction and is the trigger dysfunction of various organs and body systems.

The negative influence of intra-abdominal pressure caused by the fact that it occurs on the background of existing severe metabolic changes in vital organs and systems of the body that develop as a result of acute intestinal obstruction.

Existing experimental research papers which studied the morphological changes of internal organs caused by the main pathological process do not allow to evaluate disorders caused by persistent increase of intra-abdominal pressure.

Researches of intra-abdominal hypertension influence on pathomorphological changes of an internal after modeling and surgical treatment of acute intestinal obstruction will allow to understand better the importance of development of this complication in the early postoperative period

*The purpose of this work* is to study the influence of intra hypertension on pathomorphological changes of an internal after modeling and surgical treatment of acute intestinal obstruction (based on experiments on small laboratory animals).



**Materials and methods.** The experiment is executed on 34 laboratory rats that simulated acute obstructive intestinal obstruction by bandaging of terminal department of ilea by a rubber strip. In 24 hours reduced patency of the gastrointestinal tract by removing of the rubber strip from intestines, and increased intra-abdominal pressure by the method proposed by us, which includes input into the abdominal cavity the capacity with a certain quantity of Furacilin.

All experimental animals was divided into two groups - the main and comparison. The main group was made by 20 animals which intra-abdominal pressure was 22 mm of mercury. The comparison group was made by 14 animals which intra-abdominal pressure didn't increase.

Taking of the biological material was performed after autopsy of animals on the 12th and 24th hour after restoration of patency of the gastrointestinal tract and creating of intra hypertension.

For light-optical research, at histological research, biopsic materials of heart, lung, liver, spleen, kidney and small intestine tissues were fixed in 10% neutral formalin. Cuts were painted with hematoxylin and eosin. The descriptive method of the revealed pathological changes were used.

**Results.** During the research of a liver of animals of the both experimental groups on the 12th hour of the observation was marked local venous capillary plethora, expansion of perysynusoyid spaces, dysplasia of beam-radial structure of hepatic cells, clearing of their cytoplasm.

On 24 hour of research - the central veins of a liver are expanded and overflowed with blood, sinusoids and portal veins unevenly filled with blood, with the stasis phenomena. Perysynusoyid spaces also expanded. Hepatic cells kept their classical placement, however in cytoplasm protein adipose degeneration was observed.

The created intra-abdomina hypertension within 12 hours brought to more expressed centrolobular plethora of hepatic lobes, which are in many places discomplexed. Hepatocytes were optically empty cytoplasm with centrally placed polymorphic nuclei, including many pyknotic. In other places the cytoplasm is heterogeneous from homogeneous eosinophilic to hlybkovous.

In the main group of animals on the 24th hour of observation circulatory of blood circulation had more widespread, diffusion character, edema of spaces of Disse and periportal stroma accrued. Red blood cells in the blood vessels were hemolyzed. Central hepatic lobe beams are discomplexed and the location of hepatic cells reminded a pavement. The cytoplasm of these cells looked optically empty with a nuclei in the center. In other cells revealed dystrophic changes of various degree (fig. 1).

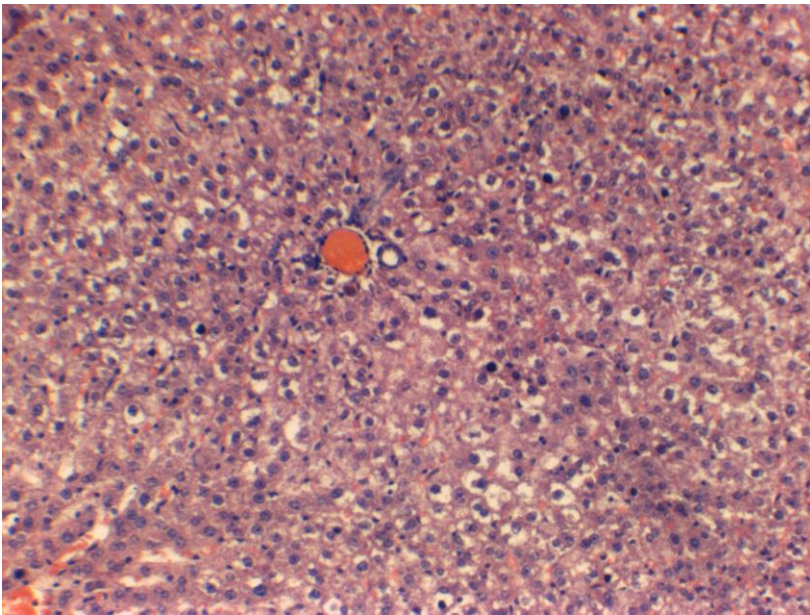


Fig. 1. Photo of a micropreparation of rat liver with created intra-abdominal hypertension lasting 24 hours after modeling and surgical treatment of acute intestinal obstruction. It is noted plethora of central veins. Diskompleksation of hepatic cells is in the form of pavement. Violation of beam-radial structure. Most cells have optically empty cytoplasm (deglykogenization). Coloring with hematoxylin and eosin.  $\times 80$ .

On the 12th and 24th hours of research renal tissue of animals of the comparison group was characterized by irregular blood cortical and medullary area, with a predominance of venous plethora. Also the moderate irregularly pronounced interstitial edema was noted. Ischemic malpighian tufts filled all gleam of a capsule of the Shymlanskogo-Bowman capsule. The epithelium of proximal and distalny departments of tubules filled their lumen, nuclei of cells are accurately visualized.

In the main group of animals on the 12th hour of observation was observed expressed plethora of stromal vessels cortical and medullar areas, especially the pyramids. Ischemic malpighian tufts occupied all gleam of Shymlanskogo-Bowman capsule. In some areas of renal tissue epithelium of seminiferous tubules is necrotic.

Under the influence of increased intra-abdominal pressure during 24 hours associated with unevenly reduced venous blood of cortical area almost complete loss of the structure of seminiferous tubules was observed, the epithelium was homogeneously eosinophilic without nuclei (Fig. 2).

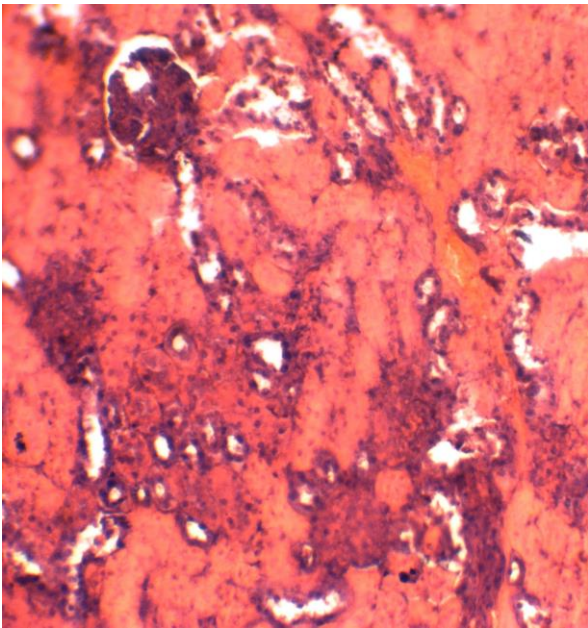


Fig. 2. Photo of the micropreparation of the rat's kidney with created intra-abdominal hypertension lasting 24 hours after modeling and surgical treatment of acute intestinal obstruction. Necrotic changes convoluted tubule epithelium. Coloring with hematoxylin and eosin.  $\times 100$ .

On the 12th hour of observation in the spleen of both research groups plethora venous sinuses of the red pulp was expressed. Due to this, in some areas characteristic histologic picture was erased. Quantity of lymphocytes is visually reduced, follicles are also reduced, without the light centers. The central arteries and arterial trabeculas were ischemic.

In the comparison group on the 24th hour was observed sharp plethora of red pulp at the expense of which lymphoid elements didn't differ. Follicles were saved, but had clearly distinct differentiation into zones. However, in the main group of animals was sharply expressed diffuse hyperemia, which was in the form of "blood" lakes and often made impression of existence of hemorrhages. Such changes were accompanied by an atrophy of lymphoid tissue.

In both experimental groups of animals on the 12th hour of research was observed plethora of capillaries and small veins of all layers of the paries of the small gut, edama of the mucus membrane, submucous basis and a muscular layer, dystrophic changes of epithelial tissue and its focal desquamation. However, in intra-abdominal hypertension were noted diffusion dystrophic changes of enterocytes, edema of all layers of the bowel paries, desquamation of the apical parts of villi and stratification of mucous-cellular masses on a surface of a mucous membrane.

On the first day of observation at animals of the comparison group was observed plethora predominantly submucosal layer of the paries of the small gut and serous membrane, which was accompanied by blood stasis and edema. In the mucous membrane stromal villi edema, dystrophic changes of enterocytes with their desquamation were occurred. In some cases collapsed actually villi. On the surface of the mucous membrane stratifications of mucous weight with impurity of desquamated cells and fragments of villi was observed.

On intra-abdominal hypertension lasting for 24 hours the total hypostasis of the paries of gut was observed. In the conditions of the increased intra-abdominal pressure the majority of vessels looked like gravitated at the expense of their compression, others - plethoric. The most expressed changes in epithelial structures were localized in the membranes of the villi. The flattening of enterocytes on tops of villi and between them was observed. Basal polarity of nuclei was often lost, a clear boundary of cells was washed away. In cytoplasm protein drops or a vacuolization were observed. The nuclei in such cells became pyknotic. The attention was drawn by an intensive desquamation of necrotic and dystrophic changed individual enterocytes and their layers in the lumen of the intestine, where they mixed up with slime (fig. 3).

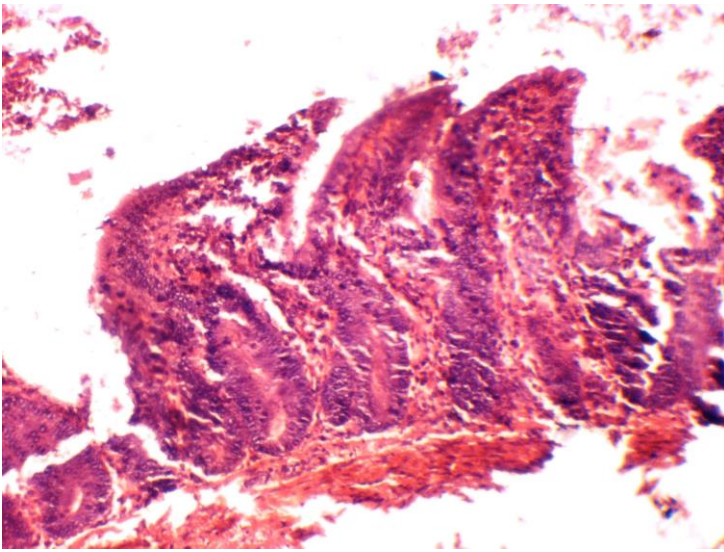


Fig. 3. Photo of the micropreparation of the a small gut of a rat with created intra-abdominal hypertension lasting 24 hours after modeling and surgical treatment of acute intestinal obstruction. The desintegrant edema of all layers of paries of a gut, the destruction of the apical parts of villi and epithelium desquamation are observed. Coloring with hematoxylin and eosin.  $\times 200$ .

The myocardium on the 12th hour of the observation was characterized by irregular blood filling of microvasculature, with a predominance of dilated plethora its venosity. Pervazal and intercellular stroma are expanded and moderately edematous. Cardiomyocytes are mainly concentrated, their cytoplasm is painted unevenly, often contained granularity. Nuclei are polymorphic, including many pyknotic. In vessels occurs blood stasis and sludge of erythrocytes. Increased intra-abdominal pressure led to a sharp plethora dilatation microvasculature, especially its venosity, expressed stromal edema. Portions of disintegration of cellular layer among which there were cells of deep disintegration of cytoplasm, fragmentations of cardiomyocytes, erasing of cellular borders with homogenization of cytoplasm and pycnosis, occasionally lysis of nuclei were noted.

In the comparison group on the 24th hour of research equally expressed plethora of capillary and venosity microvasculature was observed. Perivascular stroma is expanded, cardiomyocytes changed their tinctirial properties, namely cytoplasm unevenly absorbed dye, giving it a mosaic look. Skeletal striated was not visualised.

In the myocardium of the main group of animals grew circulatory disorders, which were shown by focal venous plethora and stromal edema, combined with dystrophic changes of cardiomyocytes. Fungal disintegration of cytoplasm, karyopyknosis and karyorhexis were often observed. Fields of fragmentation and deformation of the location of cells appeared.

During the day at the animals of the comparison group in pulmonary tissue dilated, plethoric vessels of the microvasculature, with signs of stasis were noted. In medium-sized vessels clear signs of the sludge of erythrocytes were noted. Perivascular and interstitial stroma was expanded. In some alveoluses contained serous fluid.

Intra-abdominal hypertension which was lasting for 12 hours, except above-mentioned pathomorphological changes, brought to uneven interstitial and intra-alveolar edema of lung tissue, dystelectasis, diapedesis of erythrocytes in the lumen of the alveoli and interstitium. Round separate small bronchial tubes infiltrates were observed.

Intra-abdominal hypertension during one day led to the development of total dilatation of the vasculature at all levels, blood stasis and diapedesis of erythrocytes, which acquired systemic along with a plasma transsudation. Therefore, most of the alveoli contained edema fluid and red erythrocytes. These changes occurred against a background of dystelectasis lung tissue (Fig. 4).

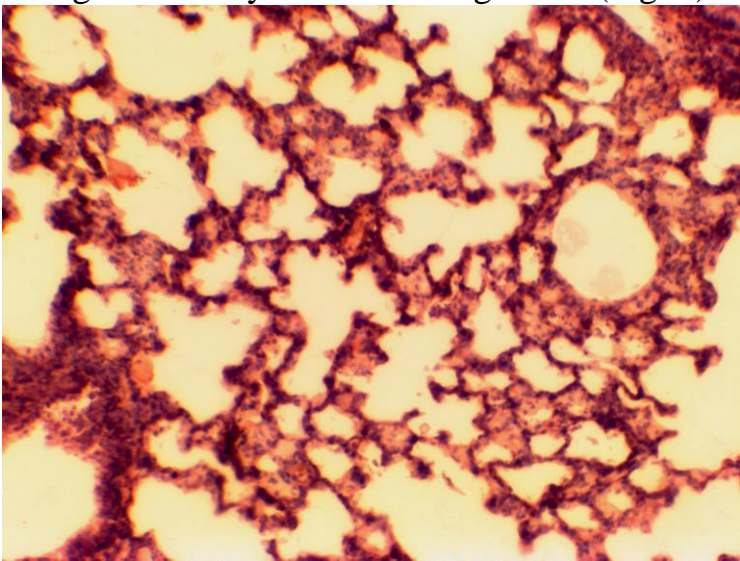


Fig. 4. Photo of the micropreparation of rat's lungs with created intra-abdominal hypertension lasting 24 hours after modeling and surgical treatment of acute intestinal obstruction. It is noted the plethora of microvasculature. In many alveoli contained edema fluid. Coloring with hematoxylin and eosin.  $\times 100$ .

Analyzing the results of the undertaken research it should be noted that finding pathomorphological changes of the studied organs have a similar pattern which is characterized by dilated expansion of vessels, mainly at the expense of venosity of the microvasculature, followed by the development of edema and dystrophy of tissues. The hypoxia which appears in result of the sudden compression of blood vessels and hypoxemia on the background of respiratory distress, stimulates such dyscirculatory disorders and promotes the rapid development of necrobiotic and necrotic changes. These pathological processes directly depend on the length of intra-

abdominal hypertension as on 24th hour of observation disorders of blood circulation, and also dystrophic changes are more generalized and deeper in their effects.

**Conclusion.** Created intra-abdominal hypertension after modeling and surgical treatment of acute intestinal obstruction during one day leads to morphological changes of tissues of internals, as plethora, edema and dystrophy, which can be regarded as the morphological equivalent of their failure.

We consider it reasonable to investigate negative influence of the growing intra-abdominal pressure on morphological condition of internals in patients with acute obturation intestinal obstruction complicated by intra-abdominal hypertension in the early postoperative period.

**Key words:** acute intestinal obstruction, abdominal pressure, abdominal hypertension.

© **Kutelmakh O.I., Chumakova Y.G., Saif Mohammed Nagm Al-Juburi**

Pirogova National Medical University in Vinnitsa, Ukraine, The Institute of Dentistry of the AMS of Ukraine (Vinnica, Medvedeva street 11); (Odessa, Rishelyevska street,6, [ahzelo1968vin@i.ua](mailto:ahzelo1968vin@i.ua))

## **THE EXPERIMENTAL MARK OF THE THERAPEUTIC ACTION OF METROXAN AT THE MODEL PERIODONTITIS**

**Introduction.** Among the large number of therapeutic agents used for local treatment of generalized periodontitis a certain role play medicines based on nanoscale silica, which have effective therapeutic properties. One of those proposed for the study of therapeutic medications is Metroxan, a nanoscale two-metric wound healing composition recommended for use at the initial phases of purulent wound healing process. In the present study, our purpose was to examine the impact of complex composition based on Metroxan nanoscale silica on the course of experimental periodontitis in rats.

**Materials and methods.** 30 male rats weighing 130-170 g, aged 2.5-3 months and receiving the vivarium diet were involved in a 25-day experiment. A peroxide type of experimental periodontitis was used as a model. Experimental animals with model periodontitis were divided into 4 equal groups. The second group was a non-treatment model; the rats from the third group were treated with Sylix as a therapeutic agent (20% paste-like suspension form); the animals from third and fourth groups were treated with Metroxan suspension in working concentrations of 1% and 4% respectively.

Method of treatment: during 10 days (the period of time that roughly corresponds to the duration of I-II phase of wound healing process in humans) the animals from third, fourth and fifth study groups were injected once daily with a large syringe the corresponding drug in the mouth atrium on both sides of the lower jaw for 3-4 minutes. The first control group consisted of rats with a healthy periodontium (6 animals).

Morphometric assessment of a dystrophic process in peridontium was performed by measuring the exposure of each molar tooth root from a tongue surface with a binocular magnifier.

The homogenate of gum mucosa from mandibular molar area was taken for biochemical studies. The level of lipid peroxidation in the studied biological material was assessed by the MDA accumulation; an inflammatory process — by the activity of hydrolytic enzymes - cathepsin D, and the degree of antiradical protection — by the activity of superoxide dismutase antioxidant enzyme.

**Results.** Morphometric study showed that bone resorption rates were almost same in all model periodontitis animals. Evaluation of gum mucosa homogenate biochemical indicators revealed the following picture: MDA and cathepsin D levels in untreated animals were almost twice as high as in healthy controls, whereas SOD activity was lower by 51%.

The administration of Syliks significantly suppressed the activity of the lipid oxidation and hydrolysis (MDA <1.3 times; cathepsin D <1.2 times), and increased the antiradical protection (SOD activity rose by 26%), but none of the studied parameters did not reach physiological level of healthy controls. The local use of 1% (MDA <1.5 times; cathepsin D <1.5 times) and 4% metroxan suspension (MDA <1.8 times; cathepsin D <1.7 times) were found most effective for reduction of MDA level and the activity of cathepsin D, but the control values were not achieved due to short period of use. And in this case, the SOD activity, which was presumably increasing (by 72% in the case of a 1% metroxan suspension, and by 85% - in the case of a 4% metroxan suspension), was still lower than in intact animals.

Compared to intact periodontium, the explicit degenerated changes of gum epithelial mucosa were quite obvious in histological gum preparations of non-treated rat models with experimental periodontitis. Some animals from the groups administered Syliks and 1% metroxan suspension demonstrated termination of inflammation process and restoration of own gum plate epithelial structure. Microscopic study of rat gum preparations, in which a 4% metroxan suspension was used, showed a picture of the inflammatory process termination, but did not present the complete regeneration of epithelium and own gum plate structural units.

**Conclusion.** Thus, the analysis of the results of the research aimed at the study of the therapeutic effects of nano-scale silica medicines and performed on peroxide periodontitis rat model suggests that the use of a 4% metroxane nanoscale composition suspension during I-II phase wound healing process according to M.I. Pyrohov scale features a pronounced anti-inflammatory effect, but inadequate stimulation of regeneration processes.

**Key words:** experimental periodontitis, metroxan, decametoxin, metronizadole, n-sized silica, polymethylsiloxane, bio-chemical, morphometric, morphological experiment.

Scientific research institute of invalid rehabilitation of Vinnitsa national Pirogov memorial medical university (str. Khmelnytske Highway 104, Vinnitsa, 21029, Ukraine)

## **MORPHOLOGICAL CHARACTERISTICS OF TISSUE IN PATIENTS WITH IMPAIRED REPARATIVE OSTEOGENESIS**

**Introduction.** Morphology induced hyperhomocysteinemia changes in patients with impaired reparative osteogenesis studied.

Objective: to investigate the features of morphological changes in tissues of patients with disorders of reparative osteogenesis in the background hyperhomocysteinemia.

**Materials and method.** On the background of hyperhomocysteinemia detected damage to blood vessels in the form of desquamation and hyperplasia of the endothelium, proliferation of smooth muscle elements of the vascular wall, aggregation and adhesion of red blood cells and platelets, clot formation with complete obliteration of the lumen of the arterial and venous vessels. Hyperhomocysteinemia content of total serum samples were ELISA set "Homocysteine EIA" (Axis-Shield, England)

### **Results.**

In the skin, muscles and nerves identified degenerative and necrotic processes, the area and severity of which depend on the degree of damage to the blood vessels and homocysteine.

Found that in patients with disorders of reparative osteogenesis of long bones in the background GHZ observed dystrophic-necrotic tissue changes, which depend on the severity of hyperhomocysteinemia.

In skeletal muscle zones marked false joint swelling and moderate degenerative changes. Edema, which spread during epimiziyem, combined with the destruction of sarcolemma of muscle fibers, partial loss of longitudinal and transverse posmuhovanosti. In some fields of tortuosity myofibrils combined with complete loss of transverse posmuhovanosti. Two specimens revealed degeneration contraction of muscle fibers with loss of longitudinal miofibrylyarnosti, formation and development of eosinophilic conglomerates fibroblastic reaction and miofibrozu. In the nerve fibers that permeated skeletal muscle observed subepinevralnyy swelling with signs of separation epinevriyu, forming sealing areas, thinning and thickening.

### **Conclusions.**

In patients with impaired reparative osteogenesis due to high levels of hyperhomocysteinemia in the area of false joints observed moderate changes in the skin, blood vessels (edema, desquamation and hyperplasia of endothelial layer, proliferation of smooth-muscle elements intravascular erythrocyte aggregation with the formation of single wall surface thrombus) (interstitial edema and development of myositis), nerves (subepinevralnyy swelling with signs of disintegration).

In patients with high hyperhomocysteinemia pathological changes in tissues deepened, developed in the skin and extensive lymphocytic infiltration-plasma; in vessels - volume areas desquamation and proliferation of endothelial hypertrophy of smooth myositis, intravascular platelet agregation and the formation of red blood



cells from multiple blood clots; muscle and nerves noted pronounced degenerative and necrotic processes that formed the background to vascular endothelial injury and thrombosis.

**Key words:** hyperhomocysteinemia, reparative osteogenesis, morphological characteristics.

© **Makogonchuk A.V.**

Vinnitsya, Ukraine

## **THE INFLUENCE OF THE AGE ON THE CURRENT OF THE REPARATIVE OSTEOGENESIS IN THE EXPERIMENT**

**Introduction.** The article is dedicated to the study of the age influence on the reparative regeneration of the bone stock in the experiment. Study of reparative regeneration of bone tissue has been widely discussed both in our country and abroad. However, this problem still remains unsolved.

**Objective:** to study age characteristics of reparative regeneration of bone tissue in the experiment.

**Material and methods.** The study was conducted on 60 adult female rats of the "Vistar", contained in standard vivarium conditions of the Institute of Gerontology of Ukraine. Rats were divided into 3 groups of 20 animals each: Group A (young) of rats aged 4 months.; Group B (mature) - rats aged 12 months.; Group C (old) - rats aged 24 months. All animals under inhalation ether anesthesia was performed fracture of the distal femur metaepiphysis. From the experimental animals were taken at 3, 5, 10 and 30 days (10 animals in each subgroup) by an overdose of ether. Taken material was subjected to histological examination.

**Results.** The results of histological analysis and histomorphometrical examination of femurs of female rats of different age are given.

In addition to neutrophils, macrophages and lymphocytes in animals younger identified field of fibroblasts, while both animals and average unit senile prisutstvali fibroblasts, which are located mainly around the forming vessels. Animals senile observed an increased density of neutrophils compared with animals in young and middle-aged.

In the formation of the vascular bed in young animals dominated capillary vessels type animals and middle-aged and senile dominated sinusoid.

**Conclusions.** It was established that regardless of the age of the animals fracture healing process proceeds from the general scheme (type seam - desmalgia: granulation tissue - fibroreticular tissue - osteoid - bone), but the staging and timing of regeneration biased towards deterioration due to animals aging.

**Key words:** reparative osteogenesis, age.

© Borisenko V.B.<sup>1</sup>, Gorgol N.I.<sup>2</sup>, Mishina M.M.<sup>2</sup>

<sup>1</sup> Kharkov Medical Academy of Post-Graduate Education ( Korchagintsev Street, 58, Kharkov, Ukraine, 61176); <sup>2</sup> Kharkov National Medical University ( Lenin Avenue,4, Kharkov, Ukraine, 61022)

## **BILIARY SEPTIC SHOCK: PECULIARITIES OF PATHOMORPHOLOGICAL CHANGES OF INTERNAL ORGANS IN EXPERIMENT**

**Introduction.** Ubiquitous growth of septic diseases number, mortality under which comprises about 40% and 80-90% - under septic shock progress or multiple organ failure is recently marked.

Mechanisms of transformation of acute cholangitis into biliary sepsis remain vague, especially severe biliary sepsis, complicated by septic shock. The description of pathomorphological changes of internal organs under such conditions is absent in literature.

Research purpose: pathomorphological study of pathogenic factors under BS, complicated by septic shock.

**Materials and methods.** Experimental research was carried on 18 rats of Vistar line with their distribution into two groups: group of comparison consisted of 6 healthy animals and main group which consisted of 12 animals. Rats of the main group were performed laparoscopy, choledochus puncture with daily crops of reference strain of E. Coli (SISC 240533) in concentration  $1 \times 10^{12}$  CFU lumen introduction. Level of manifestation of dystrophic, necrobiotic, hemodynamic and inflammatory liver, choledochus, lungs, heart, spleen, kidneys and regional lymphatic nodes changes were estimated microscopically. Average thickness of choledochus wall and its epithelium height were determined as well as activity and number of hepatic Kupfer cells.

**Results.** Lethal outcome in all animals was detected in 16-24 hours after operation.

Under microscopic research choledochus wall was thickened at the expense of edema, extensive destruction of mucosa with epithelium collapse and deep necroses. Inflammatory infiltration of choledochus wall is presented by neutrophil granulocytes and penetrate through all its depth. Wall thickness comprises  $283,39 \pm 1,91$  mcm, preserved epithelial pavement  $14,1 \pm 0,22$  mcm.

Vacuolar dystrophy and focal hepatocyte necroses were observed in liver, inflammatory infiltrates were represented by neutrophil granulocytes with admixture of macrophages. Number of Kupfer cells comprised  $209,13 \pm 1,01$  specimens in limited visual field (in group of comparison -  $253,7 \pm 1,51$ ), they were located rarely, they were minor with dense nucleus and weakly expressed cytoplasm. Weakening of Schick-positive coloring of cytoplasm demonstrate the reduction of their functional activity.

In cortical and cerebral kidneys layer expressed hemodynamic disorders with stasis, erythrocytes sludging, microthrombus as well as walls destruction in the way of endothelium swelling and desquamation, fibrin necrosis were detected.

Considerable edema of interstitium, overvascular hemorrhage were detected in heart. Contractural changes, focal sarcoplasm basophilia, expressed dystrophic changes, foci of coagulation necrosis or focal myocytolysis, expressed neutrophilic interstitium infiltration were detected in cardiomyocytes. Heart stroma was dramatically edematous. The development of DIC-syndrome was detected on the background of dramatic plethora.

Signs of respiratory distress-syndrome were detected in lungs. In alveolus cavities erythrocytes, fibrin deposits, edematous liquor, various numbers of neutrophils, "gillan membranes" were present. In small vessels and capillaries units of erythrocytes cells, fibrin bundles were detected, in bigger vessels-mixed thrombi.

Plethora of red pulp and focal neutrophil granulocytes gatherings were found in spleen. White pulp was with lymphoid follicle devastation, preferably B-zones with lymphoid follicle reduction. Reduction of lymphoid follicle with decrease of macrophages content in sinus and necrobioses of reticular elements were detected in regional lymphonodi. In 4 (33,3%) cases full spleen devastation was marked - «non-reactive» spleen and full lymphonodi devastation.

### **Conclusions**

1. Etiopathogenic factors of BS progress are cholestasis, bacteriocholia, choledochus mucosa epithelial cover and its microcircular channel destruction, leading to bacteriemia and endotoxiosis.
2. Main morphological manifestation of BS complicated by septic shock are alternative (dystrophic and necrotic) changes of various target organs with expressed hemodynamic disorders and DIC-syndrome development.
3. Inflammatory changes in internal organs under biliary sepsis are in weakly expressed nature and are mainly found in myocardium.
4. In immune organs morphological signs of their decompensation with mass destruction of immunocompetent cells are exposed.

**Key words:** biliary sepsis, biliary septic shock, modelling, morphological changes.

© **Hevkalyuk N., Gasyuk P.**

Ternopil State Medical University by I.Ya. Horbachevskiy (46000 Ternopil, st. Majdan Voli, 1)

## **STRUCTURAL AND FUNCTIONAL ORGANIZATION OF THE SECRETIONS-EXCRETIONS DEPARTMENT PAROTID SALIVARY GLANDS**

**Introduction.** It is known that the salivary glands is a special group of the secretory organs, that performs a number of functions and greatly affects the condition of the body [Bykov, 2005; Palcev et.al., 2003; Petrychshev et.al., 2002]. The study of the structure and function of the salivary glands in normal condition, their regenerative and adaptive potentials, changes in the development of the systemic diseases, disorders in the infectious diseases in recent years have been in a prominent place in

the literature of the world [Palcev et.al., 2001, 2003; Tarasenko et.al., 2002; Rabinov, 2000; Yousem et.al., 2008]. Despite the fundamental temper of many studies of the salivary glands, which are held at the present stage, the question of the basic structural mechanism of excretory of the saliva still remains unresolved.

**Objective:** to make complex morphological study of the structural and functional organization of the secretory-excretory part of the salivary glands healthy people.

**Material and methods.** Research materials were parotid gland taken after opening in healthy people who died in Poltava psychiatric hospital by Maltsev. Removed material was fixed in 10% neutral formalin solution. Produced paraffin and epoxy blocks of which get thin slices. With epoxy blocks did half-thin slices were made and painted by blue toluidin. Paraffin sections painted by hematoxylin-eosin, CHIC-altsian blue and CHIC-altsian blue+ by Bergman.

**Results and discussion.** Our histochemical studies of the excretory ducts of the salivary glands established that the multilane ciliated epithelium consists of the ciliated cells that provide motion of the mucous secretions of the goblet cells (stained by CHIC + thiamine in pink), and of short and long intercalated cells too. The recent cells are located on the basement membrane, under which the accumulation of plasmacites is revealed, which synthesize an inactive form IgA. Secretory immunoglobulin A, passing through the cytoplasm of epithelial cells, is activated by the formation of sulfhydryl groups in the protein secret. The accumulation of lymphoid tissue with the formation of the growth centers is observed around the interpartible excretory ducts, indicating the participation of lymphoid tissue in the synthesis of immunoglobulins (IgA and IgG), which play an important role in local immunity.

Acinus departments of the salivary glands consist of protein, mucous and mixed glandulocitis, which are separated by mioepithelial cells. Acinus are primarily opened into the expletive ducts, which contain the cambial elements of the epithelium, and than into the striated ducts which are lined by oxyphilic columnar epithelium. Histochemicaly stained by CHIC+ tionin blue acinus containe mixed mucocitis placed in the basal part of the cells, and myoepithelial cells are revealed around it.

In our histochemical staining of the acinos units of the parotid salivary glands by CHIC-altsian blue the protein acinus is mainly found, its cells contain the small Bergman-CHIC+ altsian blue positive protein granules. Lymfohystiocytar infiltrates are often occurred around the protein acinus in the stroma. Serous acinus in the half-thin preparats containe the cells with pale pink beads, surrounded by myoepithelial "basket type" cells, and the lateral acinus consists of the myoepithelial cells processes which are able to contract, so there is a gradual earnings of protein and mucous secretion into the lumen of the terminal unit of the salivary glands.

The intercalary ducts of the salivary glands are represent by the narrow tubes placed between the secretory acinus and striated ducts. The intercalary and striated ducts are long and well-branched in the parotid gland.

**Conclusions.** The complex morphological study of the structural and functional organization of secretory-excretory of the parotid salivary gland showed that the specific differentiation of acinar units of the salivary glands is the presence of protein

secretion that is released into the lumen of the acinus, provided appropriate topography and mioepitelialnyh epithelial cells.

**Key words:** parotid salivary gland, secretory-excretory department, structural and functional organization.

© **Burkovskiy M.I.**

Vinnitsa National Pirogov Memorial Medical University, Department of General Surgery (56 Pirogov St., Vinnitsa, 21018 Ukraine)

## **MORPHOLOGICAL CHARACTERISTIC OF DOG'S ERYTHROCYTE SHADOWS**

**Introduction.** One of the ways of increasing the efficiency of a drug effect, reduction of its dose and side effects on organs and body systems is application of the targeted transport of drugs. In this case erythrocytes are the most accessible for immobilization drugs that can be used as whole cells and as erythrocyte "containers" containing a drug (Siplivaya et al., 1999). Selective intra-arterial drug injection included into the autological erythrocyte shadows causes accumulation of the latter in the area of the inflammatory infiltrate creating its pool there (Burkovskiy, 2000; Verba, 2010). Erythrocyte shadows can be prepared by different methods and depending on the preparation method they can have different morphological traits. In particular, the erythrocyte shadows size can influence the intensity of their accumulation in the area of a pathologic process during the regional delivery. The dog is one of the experimental animals that can be involved into the study of the efficiency of the intra-arterial selective delivery of drugs included into autological erythrocyte shadows (Burkovskiy, Zheliba, 1999; Burkovskiy et al., 2011). So, the aim of our research is to study the morphological traits of dog's erythrocyte shadows prepared by different methods.

**Materials and methods.** The research involved 5 mongrels weighing 8-12 kg with observance of the main provisions of GLP (1981), Rules of performing works with the use of experimental animals (1977), Convention of the Council of Europe for the Protection of spinal animals used in experiments and for other scientific purposes of 18.03.1986, Directive of the EEC No. 609 of 24.11.1986 and Order of the Ministry of Public Health of Ukraine No. 281 of 01.11.2000. The samples of 15 ml of the venous blood were collected from the mentioned animals (into three vials, 5 ml per each, containing 5 ml of the physiological solution of sodium chloride and 2000 units of heparin each). Erythrocyte shadows from the received blood of each animal were prepared according to three methods: the first one - using the aminazine solution (Burkovskiy, Zheliba, 2001); the second - using the solution of promethazine hydrochloride (Burkovskiy et al., 2012); the third - using the solution of trifluoperazine hydrochloride (Burkovskiy et al., 2012). The received erythrocyte shadows were studied using the phase-contrast microscopy. For this purpose the microscope "MIKMED-2" with the MEDICAL IMAGE VIEW STATION and

computer image analyzer UNHSCSAImageTool v.3.0, computer program for morphological researches - Paradise was used. The diameter of erythrocyte shadows was studied in each portion by measuring it in 30 shadows in different fields of vision. Statistic processing of the received results was performed using a personal computer with the help of the program package STATISTICA 6.1. The feature distribution type in the groups was assessed using Kolmogorov test, significance of the result difference in the investigated groups - according to Kolmogorov-Smirnov criterion. The statistical level of significance was admitted as  $p < 0,05$ .

**Results. Discussions.** During preparation of erythrocyte shadows the erythrocyte ghosts lose their disk-like form and acquire the form of an ellipse or shaped circles (Pic. 1, 2, 3). The received shadows are smaller than erythrocytes and their sizes vary depending on the preparation method.

The determined sizes of dog's erythrocyte shadows prepared using the aminazine solution ranged from 1,6  $\mu\text{m}$  up to 2,6  $\mu\text{m}$ , the average size was  $2,13 \pm 0,04 \mu\text{m}$ .

The erythrocyte shadows prepared using the promethazine hydrochloride ranged from 1,0  $\mu\text{m}$  up to 2,0  $\mu\text{m}$ , their average size was  $1,47 \pm 0,05 \mu\text{m}$ .

While using trifluoperazine hydrochloride the erythrocyte shadows ranged from 1,0  $\mu\text{m}$  up to 2,0  $\mu\text{m}$ , but their average size was smaller ( $1,20 \pm 0,07 \mu\text{m}$ ) than erythrocyte shadows prepared using the promethazine hydrochloride.

Between the average sizes of dog's erythrocyte shadows prepared using different methods the statistically significant difference was determined ( $p < 0,001$ ).

**Conclusions.** 1. Dog's erythrocyte shadows prepared by different methods differ morphologically. The erythrocyte shadows received using the trifluoperazine hydrochloride have the smallest size. Erythrocyte containers produced using the aminazine solution have the largest size.

2. Different sizes of erythrocyte shadows prepared by different methods require further experimental researches concerning study of their accumulation intensity in the pathologic focus and determination of the optimal variant for their preparation.

**Key words:** dog's erythrocyte shadows, targeted transport of drugs.

© **Kashperuk-Karpiuk I.S.**

Chernivtsi, Ukraine

## **MICROSCOPIC ORGANIZATION OF SHELLS OF THE VESICourethRAL SEGMENT IN THE SECOND TRIMESTER OF THE INTRAUTERINE DEVELOPMENT**

**Introduction.** Abnormalities in bladder-segment of urinary tract lead to pathological changes both in the lower urinary tract and in the upstream parts of the urinary tract.

**Objective:** to study the structure of membranes bladder-urinaria segment in the second trimester fetuses.

**Material and methods.** The study has been carried out on 30 cadavers of 4-6 month old fetuses (161.0 – 290.0 mm PCL) by means of anatomical methods. Identified the histological sings of the vesicourethral triangle and formation of shells vesicourethral segment. The material for histological examination were fixed in buffered neutral formalin for 8-10 days. Fragments of tissue (bladder-urinaria segment of vessels) washed with running water for 1-2 days.

From the paraffin blocks produced histological sections 10 microns thick. Sections were produced using Luge microtome in one of three mutually perpendicular planes (horizontal, frontal and sagittal). The spatial structure of individual structures studied.

**Results.** In the second trimester fetuses bladder mucosa covered by transitional epithelium or cylindrical multilayered epithelium underneath traced well defined lamina propria, which are located in isolated blood vessels. In the mucosa of the bladder defined a large number of folds. Submucosa represented by loose connective tissue.

Between the layers of muscle membrane and muscle fibers are layers of connective tissue. Bunches ehternal longitudinal layer is dominated by the thickness of the inner longitudinal.

The outer longitudinal layer consists of front and rear longitudinal beams. The front extending from the apex of the bladder to his neck.

**Conclusions.** At the level of the bladder neck is defined thickening layers of the muscle membrane, which indicates the formation of internal urethral muscle-contractor urethra.

Within the apex of the triangle surface to the internal os urethra defined longitudinal fold of mucous membrane - tongue bladder.

The epithelium of the mucous membrane changes from the transition to multi-layered prismatic (from the bladder to the urethra).

Submucosa contains venous vascular plexus, their number increases in caudal direction.

The muscular coat of the bladder has 3 layers: inner, middle and outer.

At the level of the bladder neck all layers of clear and thickened considerably, indicating that the internal urethral muscle.

In the thick shell adventytsiynoyi observed a large number of different-sized blood vessels at the inner eye urethra.

**Key words:** vesicourethral segment, fetuses, anatomy.

© **Fedorovych O.A.**

Ternopil' State Medical University named after I.Ya.Gorbachevsky (m-n Voli, 1, Ternopil, 46001, Ukraine)

**THE STRUCTURAL RECONSTRUCTION OF THE RATS TONGUE VASCULAR BED AT THE VARIOUS ORIGINS BURNS**

**Introduction.** A variety of local factors (physical, chemical, traumatic) causes lesions of the oral mucosa. Etiological factor and the intensity of aggression determine the severity and prevalence of pathological process. Burns are one of the most common types of injuries of the oral mucosa, including the tongue.

**Materials and methods.** The experiments were performed at 78 white rats, weight 180-200 g, which were divided into 4 groups. The first group consisted of control animals. Chemical burn by 45% sulfuric acid and 50% sodium hydroxide solution was modeled on animals of the second and the third group under the anesthesia. The thermal burn of the fourth group of animals was established by hot metal rod.

Histological examination of tissue slices was taken from different parts of the tongue after 1, 3, 7 and 15 days after the beginning of the experiment.

**Results and discussion.** The results of the study showed that morphological changes with different character dynamics and severity after thermal and chemical burns of tongue in experimental animals were similar.

The tonus of the arteries was increased and vascular lumen was narrowed in one day after the beginning of the experiment on rats with thermal burns.

Destructive changes characterized desquamation of upper layers of oral mucosa during burns by acid. Dilation of the arteries and increasing diameter of their lumen were observed in vascular bed. At alkali burns the morphological blood vessels changes and tongue tissues were less pronounced compared with thermal and acid burns. It was also found out that there was desquamation of superficial layers of the mucous membrane, a slight enlargement of the arteries lumen and of local clumps of red blood cells in the experimental animals groups.

Previously identified lesions were developed further on the third day of the experimental observation.

The tonus of the arteries were kept increasing, stasis in many places, combined with severe venous plethora was turned in the capillaries.

Increase of middle layer tonus and narrowing of lumen were marked in arteries of different levels at burns by acid.

Venous hyperemia and mild interstitial edema were persisted.

Peculiar changes were also seen in animals with burns with alkali. On the 3rd day of the experimental observations vessels were in various functional states. Arteries were spasmodic in some places, others - on the contrary.

Histological structure of tissues and vessels morphofunctional state were restored on the 7<sup>th</sup> day of observation in animals on the background of thermal burns. The arteries kept tonus in the group of animals with acid burns. Veins, especially in the submucosa were also moderately plethoric. The moderate interstitial edema remained as a result of vessels tonus. Progression and deepening of the previous changes were established in animals with alkali burns. Generalized spasm of the arteries was histologically determined and combined with a pronounced venous hyperemia.

During the observation period of 15 days regenerative processes of reverse development in previously identified changes and restoring the original structure of the vasculature tongue occurred for all groups of experimental animals. However, if the thermal and acid burns recovery was almost complete, while alkali burns



observed proliferation of connective tissue extension intermuscular spaces and fragmentation of muscle fibers.

**Conclusions:** 1. Thermal and chemical burns of the tongue accompanied by pronounced structural changes of vasculature are naturally not identical, and dynamics, duration and intensity of expression is different.

2. The fastest changes occur as a result of thermal factor, which are the shortest in duration and reverse development. The latest changes occur in alkali burns, which are the deepest and longest. Acid burns occupy an intermediate position.

3. Spastic nature reaction of the narrowing of the arteries lumen, thickening of their walls and increased folding internal elastic membrane appear initially in thermal burns.

4. Dilated nature of the expansion of the arteries lumen, thinning of their walls and reducing of internal elastic membrane appear at chemical burns.

**Key words:** tongue , arteries, mucous membrane, thermal, chemical burn.

© **Pashinska O.S.**

Vinnitsa National Pirogov Memorial Medical University (56 Pirogov Str., Vinnitsa, 21018 Ukraine)

## **INFLUENCE OF VINBORONE AND MILDRONAT ON THE STRUCTURE OF MYOCARDIUM AT EXPERIMENTAL ALCOHOL CARDIOMYOPATHY IN RATS**

**Introduction.** One of the serious complications of alcohol is the development of alcohol cardiomyopathy (AKMP).

The pathogenesis AKMP is a lasting impact of alcohol and its metabolite acetaldehyde on the myocardium. According to the literature [Kapustin, 2004; Rom et al. 2012] it is known that functional impairment in AKMP accompanied by destructive changes in the heart muscle.

**Objective:** To study the effect vinborone, compared with mildronate on morphological changes in the myocardium of rats with experimental alcoholic cardiomyopathy.

**Materials and methods.** Experiments conducted on 56 male rats weighing 180-230 g rats were kept in standard vivarium VNMU with free access to food and water. Experimental toxic alcoholic heart disease simulated intragastric administration to rats of 50% ethanol (6 g / kg) for 9 weeks.

Animals were divided into 4 groups: the first group, intact, the second group of animals with AKMP untreated (control), 3rd and 4th groups - animal AKMP treated vinborone and mildronate respectively. Treatment of experimental AKMP conducted separately vinborone (5 mg / kg) and mildronate (50 mg /kg ) in 2 divided doses for two weeks, starting from the 2nd day after modeling pathological condition.

**Results.** Investigation of the morphological structure of cardiomyocytes was performed using histological methods using light microscopy.

Treatment of experimental AKMP in rats using vinborone weakens morphological manifestations of myocardial dystrophy: reduced hemodynamic disturbances and signs of fatty degeneration, weakened muscle expression and perivascular sclerosis in damaged heart muscle. Based on the results of the studies vinborone has the same effect as that of the drug under experiment end can be recommended for clinical study of its efficacy in the treatment of patients with AKMP.

**Conclusion:**

1. Course (14 days) treatment of experimental alcoholic cardiomyopathy using vinborone dose (5 mg / kg), as well as mildronate reduced hemodynamic disturbances in the myocardium of rats.

2. Amid the treatment of experimental alcoholic cardiomyopathy of vinborone reduced fatty degeneration in damaged heart muscle.

Based on the results of the studies of vinborone has the same effect as that of the drug under experiment end can be recommended for clinical study of its efficacy in the treatment of patients with AKMP.

**Key words:** vinboron, mildronat, alcohol cardiomyopathy

© **Pyda V.P.**

I.Ya.Horbachevsky Ternopil State Medical University Department of pharmacology with clinical pharmacology (m. Voli, 1, Ternopil, 46001, Ukraine)

## **STRUCTURAL CHANGES IN THE RAT LIVER AT THE ACUTE TETRACHLOROMETHANE HEPATITIS AND ITS CORRECTION BY THE MALE BUDS OF SEA-BUCKTHORN THICK EXTRACT**

**Introduction.** The rapid development of the industry at this stage leads to the increasing in the number of foreign, toxic compounds that can wound the liver. Investigation of the liver cells damage by the hepatotropic poison - tetrachloromethane acquired great value [Huberhryts, 2002].

Pharmacotherapy of the acute and chronic hepatitis, especially toxic (alcohol, chemical, medical, radiation etiology), refers to the actual problems of the modern medicine, because the significant structural and functional changes in liver cells by this disease require the prolonged treatment and comprehensive therapeutic approach. Traditionally, patients with acute and chronic hepatitis assigned hepatoprotectors with different mechanism of action [Degtyareva, 2000].

Therefore, the search and study of the impact of new correction factors (antioxidants, immunomodulators of plant material and dosage forms based on it) to metabolic disorders caused by a variety of xenobiotics is actual. In this direction, our attention was attracted by a new pharmacological substance – male buds of the sea-buckthorn thick extract.

We have conducted histological studies of the structure of liver in the conditions of the acute tetrachloromethane hepatitis and after the correction by the extract of male buds of sea-buckthorn and silibor.

**Materials and methods.** Experiments performed on 48 white mongrel male rats weighing 180-200 g, which were kept on a standard diet of the I. Ya. Horbachevsky TSMU vivarium. Animals were divided into 4 groups (12 animals per group): the first group - intact healthy animals that received saline solution; the second group of animals were rats with simulated acute toxic hepatitis by intraperitoneal administration of tetrachloromethane every other day during seven days in a 50 % oil solution at a dose of 0,2 ml per animal [Stefanov, 2002]. For other groups of animals after simulated pathology correction of the toxic hepatitis was conducted daily intragastric; the third group - correction was conducted by the thick sea buckthorn extract of male buds in a dose of 100 mg / kg; the fourth group - silibor in a dose of 50 mg / kg [Stefanov, 2002]. Euthanasia was performed with the usage of sodium thiopental on the 4th and 7th day of correction. Samples of the body fixed in 10% solution of formalin, dehydrated in alcohols of increasing concentration and poured by tseloidine-paraffin according to conventional methods. Sections were stained with hematoxylin and eosin [Afanasyev, 1999, Ulumbekova, 1997]. Review of micropreparations performed under a microscope Mikros 400. Photomicrography of the microscopic imaging performed with a digital camera Nikon Cool Pix 4500.

**Results. Discussion.** Studies of the animal liver structure at the modeling toxic organ damage showed that microscopic particles organization was relatively preserved. Central veins were moderately dilated and sinusoidal blood capillary poorly profiled, in their existing gaps were isolated macrophages and erythrocytes. The vessels of the portal tracts and bile ducts also expanded, and perivascular spaces infiltrated by lymphocytes and histiocytes.

Hepatocytes was remained stored on the periphery of the liver lobules. Dystrophic, necrotic changes in cells that were shown as enlightened parts or granular cytoplasm savings in it were dominated centro lobular. There were hyaline droplets protein and fatty atomized dystrophy. Individual cells do not contain nuclei. Along with altered hepatocytes were observed dual hepatocytes (Fig. 1).

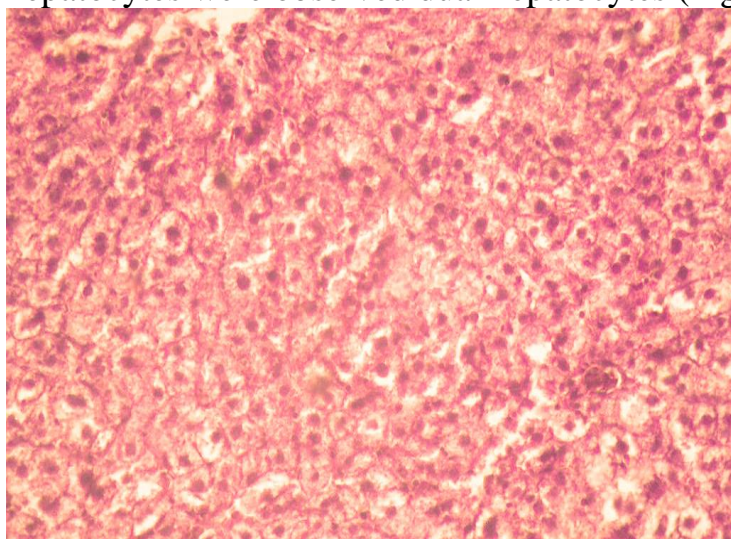


Fig. 1. Histological condition of the liver in the formation of acute toxic hepatitis on the fourth day of the experiment. Coloring by hematoxylin and eosin. x 160.

Histological investigation of the animals liver held on the 7th day of the toxic lesions, found that the structure of the beam particles remained preserved. Enlighten of the central veins looked dilated and were filled with erythrocytes. Sinusoidal hemocapillaries visualized bad, in the content of their walls existing flat form endothelial and more large Kupffer cells. Portal tracts moderately infiltrated by lymphocytes and histiocytes.

Hepatocytes as centro lobular plots of particles, and on the periphery have different sizes and shape. In the cytoplasm of hepatocytes available its quickened plot and picnotic modified kernel. Were also seen phenomenon of protein-hyaline droplet dystrophy, in the part of cells were observed phenomena of necrosis (Fig. 2).

Enlighten of the central veins moderately dilated, and sinusoidal blood capillary poorly visualized, in their walls existing Kupffer cells. Connective tissue of the portal tracts looked mildly swollen, but lympho-histiocytic infiltrates were minor. Bile ducts within the portal tracts had expanded enlighten, their walls was clearly contoured by epithelial cells.

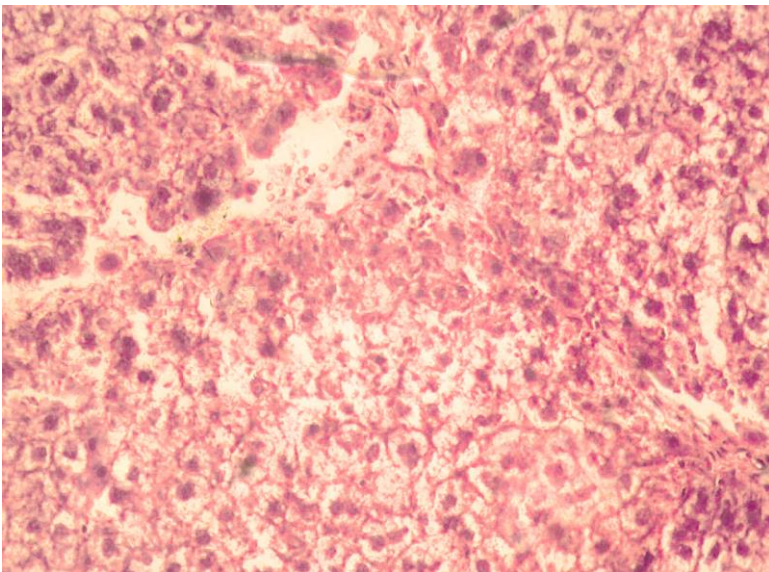


Fig. 2. Histological changes in the liver in experimental acute toxic hepatitis on the seventh day of the experiment. Coloring by hematoxylin and eosin. x 160.

In the content of particles centro lobular hepatocytes have different sizes, their cytoplasm intensely colored, contains clearly contoured basophilic nucleus. The central area of the liver lobules hepatocytes constituted, which increased in size with eosinophilic, fine cytoplasm. Cells of the peripheral areas of the hepatic lobule were with the signs of hyaline-droplet dystrophy.

At the histological examination of the liver of animals on the 7th day of the experiment with toxic hepatitis using the extract of sea-buckthorn was found that lobular-beam body organizing was preserved.

Enlighten central veins were moderate, wall of the sinusoidal capillaries were clear. In the perivascular spaces around the vessels portal tracts the small lympho-

histiocytic infiltrates contained. Most hepatocytes are the same size, their cytoplasm was oxyphilic and fine-grained. Nuclei had basophilic carioplasma clearly contoured. Only a few hepatocytes were with the signs of hydropic dystrophy (Fig. 3).

Microscopic studies of the liver on the 4<sup>th</sup> day in animals with toxic lesions after correction by silibor showed that the structure of liver lobules was preserved. Enlighten central veins looked moderately expanded, sinusoidal capillaries were also expanded, with clear contours and contained a moderate number of macrophages.

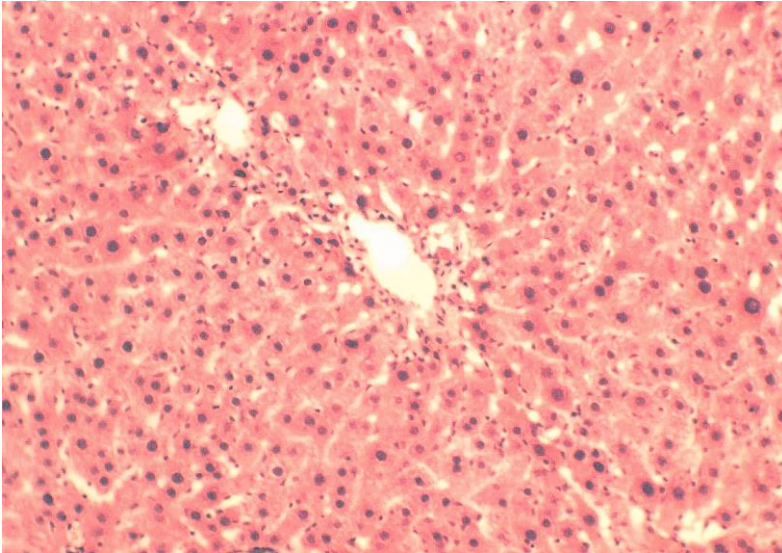


Fig. 3. Histological condition of the liver in acute toxic hepatitis and application of extract of sea-buckthorn on the seventh day of the experiment. Coloring by hematoxylin and eosin. x 160.

Preferably in the intermediate area of liver lobules altered hepatocytes were revealed with the grit cytoplasm and picnotic, basophilic nuclei (Fig. 4). Vessels of the portal tracts were moderately dilated and plethoric, perivascular spaces were moderately infiltrated by lympho-histiocytic infiltrate. Bile ducts were slightly dilated.

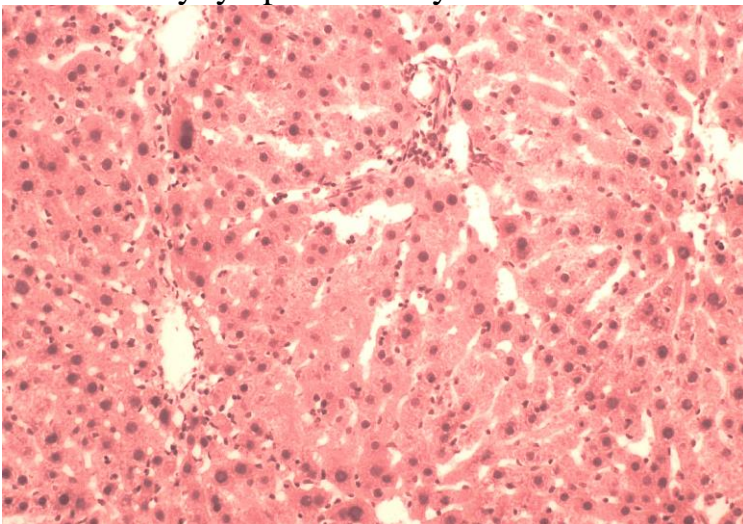


Fig. 4. Histological condition of the liver in acute toxic hepatitis and application of silibor on the fourth day of the experiment. Coloring by hematoxylin and eosin. x 160.

Histological investigation of the liver on the 7th day in animals with toxic lesion at the application of silibor showed that the structure of the organ had lobular-beam structure. Enlighten of the central veins were preserved, and sinusoidal capillaries

were moderately dilated. Their wall had clear, flat endothelial cells and some Kupffer cells.

Hepatocytes in the content of the beams were mainly the same size well contoured, basophilic nuclei and moderate oxyphilic cytoplasm. Only in the intermediate areas of particles present altered hepatocytes that had light cytoplasm and small nuclei. In the portal tracts vessels and bile ducts were intact, moderately plethoric, perivascular zones were slightly infiltrated by leukocytes (Fig. 5).

Conducted histological investigations of the liver at the experimental toxic hepatitis in the conditions of the male buds of sea-buckthorn extract usage found a positive effect of the drug on the structural components of the body. This is manifested by the less pronounced changes of vasculature, better integrity of hepato-beam organization of the body and a decreasing in the degree of hepatocytes destruction. The positive effect of the drug on the structure of the body was better on the seventh day of the experiment.

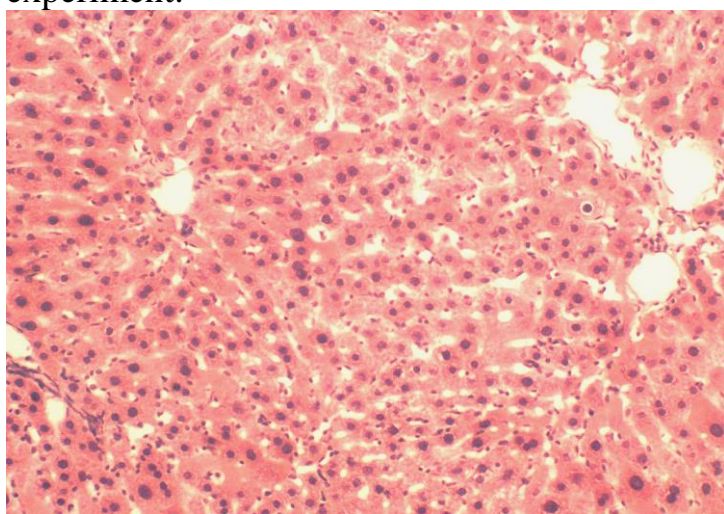


Fig. 5. Histological condition of the liver on the seventh day of the experiment in acute toxic hepatitis and application of silibor. Coloring by hematoxylin and eosin. x 160.

### **Conclusions.**

1. The usage of the male buds of sea-buckthorn extract with toxic hepatitis led to the preservation of lobular-beam organization of the liver.
2. Male buds of sea-buckthorn thick extract showed membranoprotective and hepatoprotective properties, that confirmed by the restoration of the structure of hepatocytes.

The results indicate on the promising of the further studying of the pharmacological agent with the purpose to implement it in the practical pharmacy and medicine.

**Key words:** liver, acute tetrachloromethane hepatitis, male buds of sea-buckthorn thick extract, silibor.

© Hurskyy O.S., Polyova S.P., Sarafinyuk L.A.

Vinnytsia National Medical University named after M.I.Pirogov

## MORPHOLOGICAL CHANGES OF UTEROPLACENTAL AREA IN WOMEN WITH PULMONARY TUBERCULOSIS

**Introduction.** Obscure questions about TB utero-placental site. Defeat trophoblastic villi cover chorionic products contributes violation placental hormones and specific placental proteins. The resulting circulatory hypoxia, which leads to slower maturation chorion and the functional placental dysfunction.

It is necessary to establish the causes of changes in uterine-placental area in pregnant women, patients with pulmonary tuberculosis.

Objective: to conduct research structures uteroplacental area in pregnant women, patients with pulmonary tuberculosis, depending on the activity of tuberculosis.

**Material and methods.** The analysis of morphological changes in 17 biopsies of uterine-placental area in pregnant women, patients with pulmonary tuberculosis.

Samples biopsies uteroplacental areas received during caesarean section. At Sannomiya microtome serial histological sections prepared thickness of 5 mm. From the observation purpose after dewaxing sections stained with hematoxylin, eosin, followed by computer morphometry objects in histological, histochemical and immunohistochemical preparations.

**Results.** Analyzed are changes in the structure of uteroplacental area, depending on the activity of tuberculosis.

Proliferative index (based on immunohistochemical techniques proliferative cell nuclear antigen - PCNA) in the control group mothers was  $8,3 \pm 0,15$ , in the study group - respectively  $2,2 \pm 0,18$  and  $4,2 \pm 0,16$ .

Estimated percentage of spiral arteries of the uterus with gestational complete restructuring. The results of calculation of the proportion of spiral arteries of the uterus with gestational complete restructuring showed that in the control group it was -  $92 \pm 3,5$ ; in the study group -  $61 \pm 3,1$ ; and  $70 \pm 2,3$  respectively. Average tsytotrofoblastychny cells per unit area utero-placental area in the control group was  $29,1 \pm 0,82 \text{ um}^2$ ; in osnovniy-  $6,2 \pm 0,45 \text{ um}^2$  and  $16,2 \pm 0,64 \text{ um}^2$  respectively.

In pulmonary tuberculosis several times the quantity of tsytotrofoblastychny cells per unit area chorionic villi. Lack of restructuring gestational uterine spiral arteries was determined by a decrease in the number of cells that carry the specified adjustment. In utero-placental site not found violations proliferation mothers in the intervention group compared with the control.

**Conclusions.** It is shown that in the context of newly diagnosed tuberculosis in uteroplacental site morphohistochemical changes occur that cause obstetric complications in this group of women.

The results of the morphological study of uteroplacental areas of pregnant women biopsies, patients with pulmonary tuberculosis.

The pathogenesis of placental dysfunction in conditions of TB in pregnant women caused morphological changes chorion.

The reason for violation of maturation chorionic villous trophoblast and destruction chorionic villi are relative ischemia intervillous spaces placenta caused by the presence of inflammation uteroplacental plot against the backdrop of tuberculosis.

**Key words:** tuberculosis, placenta, diagnosis, morphology.

© Chen Vey<sup>1</sup>, S.I.Morozova<sup>1</sup>, M.V.Mnikhovich<sup>2,3</sup>, G.P.Kazantseva<sup>1</sup>, El Uazzani Mokhammed<sup>1</sup>, S.A.Bezmen<sup>1</sup>, Ye.S.Babushkina<sup>1</sup>

<sup>1</sup>Ryazan I. P. Pavlov State Medical University; <sup>2</sup>Research Institute of Human Morphology, RAMS; <sup>3</sup>Russian National Research N. I. Pirogov Medical University, Moscow

## EXPERIMENTAL HISTOLOGICAL ANALYSIS OF USING ROYAL JELLY AND PHYTOECDYSTEROIDS IN DEEP CARIES TREATMENT

**Introduction.** The paper covers an experimental substantiation of the effectiveness of using complex medical product, based on royal jelly and phytoecdysteroids in deep caries treatment.

Caries is one of the main problems in dentistry. This is due to prevalence of this illness and its' consequences, leading to the loss of teeth. In deep caries pathological changes take place in pulp of involved tooth.

In process of dental caries treatment, especially of its' acute form, the main value obtains a complex filling.

Different types of drugs with anti-inflammatory, antiseptic, anesthetic, odontotropic properties to dental pulp are used currently. Interest in phytotherapeutic and apitherapeutic remedies has increased in recent years of theirs' properties necessary for treatment, such as harmless, cheapness, and their effectiveness as of synthetic drugs.

The *aim* of the study is to carry-out an experimental morphological substantiation of using remedy, based on royal jelly and phytoecdysteroids in deep caries treatment.

**Materials and methods.** Experimental part of the study was carried out on 184 cheek-teeth of white inbred male rats in the amount of 102 and with the weight of 170-250 g. Duration of the experiment was 6 months. Animals were handled with the principles of bioethics, rules of laboratory investigations and ethics, according to European Convention for the Protection of Vertebrate Animals (Strasbourg, France, 1985).

Animals were divided into two groups, depending of the type of complex filling. In the first group (35 teeth) tooth-paste based on the complex of royal jelly and phytoecdysteroids (tooth-paste MMF) was used as a complex filling; in the second group (30 teeth) tooth-paste "Daikal".

Histological structure of dentine and pulp was also studied in 23 intact teeth to comparative evaluation of changes, developing in deep caries.

Teeth were separated together with surrounding bone tissue. Lower jaw was removed and fixed entirely with 10% neutral formalin solution for 72 hours, decalcificated in 10% solution of nitric acid for 14 days, dehydrated in ethanol of ascending concentration and isopropanol, embedded in paraffin. 10 µm microscopic sections were stained with hematoxylin and eosin, by Van Geison method. Morphology of



dentinal canaliculi and stroma, odontoblasts and extracellular matrix was estimated with scanning electron microscopy (microscope Hitachi S405A, accelerating voltage 15 kV).

**Results.** Histological investigation of dentine and pulp in teeth with deep caries on 30<sup>th</sup> day revealed in main group (tooth-paste MMF) processes of regeneration. Dentine canaliculi were regular orientated, but odontoblasts orientated chaotic. The increase of fibroblast-like cells number was noticed in the pulp, indicated the increase of odontoblasts activity and stimulating effect of treatment. Odontoblasts were presented by a single layer of cylindrical cells with increased bulk density.

On scanning electron microscopy fragmentation immersion of microparticles and fineness substance in separate tubules was found. Using complex filling “Daikal” pulp necrosis, predentin absence and its dystrophy were found, also as disorganization in odontoblast layer, microcavities and microspaces between the cells.

Treatment of deep caries with tooth-paste MMF showed on the 180 day a complete obliteration of dentinal tubules and mineralization of reparative dentine.

**Conclusion.** Experimental morphological study of combined complex filling MMF and calcium containing complex filling “Daikal” revealed a significant difference in the results of treatment.

Effectiveness of “MMF” was proved by the condition of hard tissues, pulp, and the dynamics of reparative dentine generation.

Comparative analysis of using “MMF” in treatment of deep caries pointed the advantages of this complex filling, possessing antibacterial, antiinflammatory, sorption and dentine protective abilities.

Thus, the complex filling “MMF” possesses a strong odontotropic action in comparison with calcium containing complex filling “Daikal”. Using complex filling “MMF” reduces probability of complication and may be used as an alternative method of deep caries treatment.

**Key words:** deep caries, royal jelly, phytoecdysteroids, morphological study

© **Schpak I.V.**

Odessa, Ukraine

## **PROGNOSTIC VALUE OF MORPHOLOGICAL ESTIMATION OF THE STATE OF PLACENTAS OF WOMEN'S FETUS WHO CARRIED INFLUENZA A/H1N1**

**Introduction.** The morphological estimation of the state of placentas of the women's fetus who carried influenza A/H1N1 can have prognostic value for verification of placental dysfunction and its connection with ante-, intranatal stress of the fetus, the syndrome of retardation of the fetus' growth, inborn development corporals, antenatal infection [Sytnikova, 2008].

The morphological changes of the women's placentas, who carried influenza A/H1N1, are conditioned with the compensatory and adaptative mechanisms of the fetus placental complex and how up with the signs of the "aging" of the placenta, that is the presence of the centers of the calcifications [Sytnikova 2008], that characterizes the metabolic process of the fetus placental complex and can be the reasons of the vascular dystonia [Mozgovaya 2003].

*The purpose of the work* was to study character peculiarities of the women's placentas in the case of their passing of pregnancy on the background of influenza A/H1N1.

**Materials and methods.** The 15 placentas of the uncomplicated births in time have been studied and the 15 ones of the women who carried Influenza A/H1N1. Afterbirths were explored by the method of A.P. Milovanova and A.I. Brusilovskiy in the modification of K.P. Kalashnikova (1986). The weight, volume, form, diameter, thickness, colour of te fetus and mother's surfaces, the presence of the infractions, their numbers, sizes, localization were explored in the non-fixed placenta. The fetus placental coefficient (FPC) was defined.

**Results.** The uncomplicated births the middle-weight of placentas of fetus of sex of men made  $556,1 \pm 33,4$  g, volume -  $501,2 \pm 30,1 \text{ cm}^3$ , fetus-placenta coefficient (FPC) - 0,15, and woman's -  $535,3 \pm 32,1$ g,  $466,5 \pm 27,9 \text{ cm}^3$ , FPC - 0,16, accordingly.

The placentas of this group were characterized with active adaptationed and scray processes in central and regional parts.

The flow of pregnancy on the background of Influenza A/H1N1 showed up the decline of middle-weight and volume of placenta.

The fetus of sex of men the middle-weight of placentas made  $412,3 \pm 24,7$  g, volume -  $409,7 \pm 24,6 \text{ cm}^3$ , FPC - 0,13, woman's -  $407,9 \pm 24,5$  g,  $403,5 \pm 24,2 \text{ cm}^3$ , FPC - 0,13, accordingly.

The characteristic features of placentas of women who carried Influenza A/H1N1 is diminishing of weight, volume of placenta, a presence is simultaneous hemodynamic, involutive-dystrophic and inflammatory processes of different degree of expressed.

**Conclusions.** The women who carried influenza A/H1N1 have the morphological changes in the placenta their degree of intensity depends on the term and on the complexity of the illness.

2. The main role is given to the damages of the endothelial system of fetus placental complex in forming of the morphological changes in the placentas of pregnant women who carried influenza A/H1N1.

3. In forming of placenta dysfunction of the pregnant women with a Influenza A (H1N1) the proper role is taken violation of the circulations of blood in the system mother - placenta - fetus in investigation of angiopathy.

**Key words:** pregnancy, virus of flu of A/H1N1, first trimester.

Bukovinian State Medical University, Department of Human Anatomy Named after M.H.Turkevych (Ryz'ka st. 1 City of Chernivtsi, 58002, Ukraine)

## **GENDER-AGE CHARACTERISTICS OF MORPHOGENESIS AND FORMING OF THE TOPOGRAPHY OF THE URETHRA DURING THE PREFETAL PERIOD OF HUMAN ONTOGENESIS**

**Introduction.** The question of sources and the time of the appearance of the urethral anlage have interested many researchers of different specialities. Scientists have used various methods of researches that may explain such a divergence, particularly in the characteristic of the term of the appearance of the anlage and the development of the urethra at early stages of human ontogenesis. Bibliographical sources elucidate isolated data about structural changes of the mesonephric (the wolffian duct) and paramesonephric (Müller's duct) ducts and correlative interrelations of the derivatives of the urogenital sinus in human prefetuses (Khmara, Marchuk, 2003; Marchuk, 2006; Pykaliuk, 2011). The signs of the organization of the urogenital sinus appear for the first time at the beginning of the 5<sup>th</sup> week of embryogenesis. At the end of the 8<sup>th</sup> week of the intrauterine development a start of the delimitation of the urogenital sinus into the bladder and urethra is observed (Khmara, 2000). The source of the formation of the prostatic part of the urethra is the caudal portion of the urogenital sinus. At the end of the prefetal period of ontogenesis the topographoanatomical correlations between the derivatives of the urogenital sinus, in particular, the anlages of the urinary bladder and urethra change (Khmara). At the end of the 3<sup>d</sup> month of the antenatal development two urethral plicae close over the urethral plate, forming the urethra, which does not reach the apex of the penis (Sadler, 2001).

Thus, the information about the sources of forming the female urethra, separate parts of the male urethra, the organization of their topography and the dynamics of the length of the urethra during the prenatal period of human ontogenesis are not systematized.

The object of our research was ascertaining the sources of the origin, the time of the appearance of the anlage of the urethra and genital peculiar features of the organization of its topography in the prefetal period of human ontogenesis.

**Material and methods.** The research has been carried out on 15 series of histological sections of human prefetuses aged 7-12 weeks (14.0-79.0 mm of the parietococcygeal length (PCL) by means of the methods of microscopy and morphometry.

**Results.** The urogenital sinus (US) in 7-week old prefetuses (14.0-20.5 mm PCL) is represented by a somewhat bent tube with its convexity directed backwards. No demarcation of the US cavity into the urinary bladder and urethra is observed at this stage of the development. The paramesonephric ducts (PMDs) situated separately along the whole length and only in the lower region somewhat drawn together are traced in prefetuses – 16.0-17.5 mm PCL laterally from the mesonephric ducts (MDs). Each of the ducts is surrounded by a layer of the mesenchyma, a general mesenchymal membrane having been formed around the MDs and PMDs. The US

form at the level of the confluence of the MDs is approximated to an oval one. The walls of the MDs are built up of the epithelial lining surrounded by a slight layer of undifferentiated mesenchyma. The epithelium of the mucous membrane along the greater length of the US is made up of 3-4 layers of cuboid cells with nuclei of an elongated form. In the upper portion of the US the epithelium is somewhat thinner, its cells being arranged in 2-3 layers. The thickness, of the US walls makes up 150-165  $\mu\text{m}$ . The MDs are revealed on the US posterior wall (at a distance of 0.8-1.0 mm above its inferior end. A dilatation of the upper portion of the US and its flattening in a ventro dorsal direction are observed at this stage of embryogenesis. The dimensions of the US cavity equal 86x220  $\mu\text{m}$  more caudally from the openings of the MDs, whereas more cranially from the openings of these ducts the transverse measurements of the US make up 230x375  $\mu\text{m}$ . The PMDs in the form of a longitudinal diverticulum of the coelomic epithelium are located next to the MD. The caudal ends of the PMDs terminate blindly in the US. The diameter of the MDs (18-20  $\mu\text{m}$ ) in prefetuses of the male gender exceeds the diameter of the PMDs (12-14  $\mu\text{m}$ ). In the prefetuses, measuring 17.5-19.0  $\mu\text{m}$  PCL the US reaches 1.8-2.0 mm in length. Two portions are differentiated in the US: the proximal (pelvic) and distal phallic. The latter portion is elongated in a sagittal direction, connected with the genital eminence and is separated by the urogenital membrane. Subsequently, upon the rupture of the posterior portion of the urogenital membrane the primary urogenital foramen is formed, it is restricted by two genital folds that arise on the inferior surface of the genital eminence. The PMDs at the level of the ostium of the ureters fuse between themselves and open with a common ostium on the posterior wall of the US, forming Müller's hillock with thickened walls which is a slight epithelial haustrum of the distal end of the PMDs, protruding into the US lumen. The proximal ends of the PMDs preserve a separate passage. The MDs in prefetuses proceed separately along the whole length, their caudal ends turn down in an arched manner forward and upwards. The MDs are in close interrelations with the posterior wall of the US and open next to the opening of the PMDs that fused. A marked predominance of the PMD lumen over the lumen of the MDs in human prefetuses gives every reason to suppose that further development will proceed after the female gender. There gradually occurs a reduction of the PMDs in a craniocaudal direction in prefetuses of the female gender. Some smoothing of the arched passage of the caudal ends of the MDs occurs subsequently (prefetuses 22.0-26.0 mm PCL), their terminal portions which had an ascending direction in 7-week old prefetuses penetrate into the posterior wall of the urethra perpendicularly, and at the end of the eighth week of the intrauterine development at some angle, having a descending direction. The distal portions of the PMDs pass in front of the MDs, change the longitudinal direction for an oblique one and are arranged more medially than the latter. The US length makes up 2.3-2.6 mm, it uniformly narrows in a caudal direction. The US cavity is lined by the stratified cuboidal epithelium.

There appears a poorly defined isthmus in prefetuses 29.0-32.0 mm PCL as a result of a convexity of the posterior wall of the US, the neck of the urinary bladder being formed in its place afterwards. The urinary bladder develops in prefetuses, measuring 33.0-37.0 mm PCL from the proximal portion of the US, which is located above the

isthmus, whereas from the distal portion of the US – the urethra. The epithelial layer of the anlage of the urinary bladder is represented by a multilayer of cells. The cells of the mesenchyma closer to the epithelial layer are arranged loosely and those that are on the outside – become compact and that is to be regarded as an anlage of the muscular membrane of the urinary bladder. A narrowed portion of the cavity of the urinary bladder – the neck of the bladder is identified due to a separation of the ureteral ostia and those of the MDs more caudally from the ureters. The latter transforms into the US without a sharp boundary on the lower one third of the pelvic part of the US there is a proliferation of the epithelium which narrows the lumen of the sinus, gradually fills it in consequence of which the US lumen assumes a stellate form on transverse sections. The US cavity is somewhat larger more cranially from the openings of the MDs. The US wall is built up of the mucous coat covered by the stratified cuboidal epithelium and mesenchyma. The thickness of the US wall in different regions varies from 205 to 230  $\mu\text{m}$ . As a result of an intensive multiplication of the mesenchymal cells a slight diverticulum – 18-20  $\mu\text{m}$  in height is identified along the anterior surface of the posterior wall of the US starting from the neck of the urinary bladder that is the beginning of the formation of the urethral crest. At this stage further delimitation of the US into an anlage of the bladder and urethra goes on. However, a differentiation of the cells of the urethral mesenchyma has not been detected yet.

Throughout the 9<sup>th</sup> week of embryogenesis (prefetuses 31.0-41.0 mm PCL) a delimitation of the US cavity into the urinary bladder and urethra becomes more evident. A compression of the initial portion of the urethra in a ventro-dorsal direction is identified due to an increase of the seminal hillock. The pelvic portion of the US has a crescent – shaped form on transverse sections. At this stage of development the urinary bladder assumes an elongated form, its dimensions increase, an external longitudinal and circular layers of the muscular cells are clearly identified. The thickness of the walls of the urinary bladder constitutes 180-210  $\mu\text{m}$ . the mucous membrane becomes thicker, reaching 32-38  $\mu\text{m}$ , its cells being arranged in 5-6 layers. The muscular fibers of the posterior wall of the urinary bladder are developed best of all. The structure of the wall of the urinary bladder more caudally from the confluence of the ureters differs from the structure of its wall in the region of the body. The muscular layer consists only of longitudinal fascicles which pass over here from the body of the urinary bladder and to the cranial portions of the US. The latter in the region of the seminal hillock in prefetuses of the male gender or Müller's hillock in female prefetuses dilates in a transverse direction. The upper part of the cavity of the urinary bladder in prefetuses 38.0-41.0  $\mu\text{m}$  PCL has round outlines, whereas the lower part is of a stellate form on transverse sections due to the formation of folds – 28-36  $\mu\text{m}$  high. Approaching the level of the ureters, the cavity of the urinary bladder flattens noticeably in a ventrodorsal direction. The highest transverse measurements of the cavity of the urinary bladder make up 140x520  $\mu\text{m}$ , whereas in the region of the uterine neck they equal 80x270  $\mu\text{m}$  and at the level of the openings of the MDs – 105x360  $\mu\text{m}$ . A trigone and a fundus located in the frontal plane are singled out on the dorsal wall of the urinary bladder. A circular layer of muscular cells is detected in the region of the neck of the urinary bladder, better

developed on its anterior wall. Such a circular layer is revealed along the whole length of the US pelvic part.

At the beginning of the 10<sup>th</sup> week of embryogenesis (prefetuses 42.0-46.0 mm PCL) an irregular growth of the proximal and distal portions of the MDs is observed in the region located at the level of the neck of the urinary bladder, a considerable difference of the value of their external diameter more cranially and caudally from the neck of the urinary bladder being indicative of it. On a prefetus – 46mm PCL the transverse size of the cavity of the urinary bladder over the ureteral ostia makes up 130x180  $\mu\text{m}$ , in the region of the neck of the bladder – 60x320  $\mu\text{m}$ , below the neck – 90x390  $\mu\text{m}$ . In prefetuses of the male gender there occurs a partial reduction of the PMDs which manifests itself in the obliteration of their lumen and a considerable decrease of the size of the epithelial cells. As a result of these changes in the wall of the PMDs their middle portions assume the form of a thin cellular band. A thickening of circularly oriented muscular cells is not determined in the region of the internal opening of the urethra. Solitary arteries – 18-24  $\mu\text{m}$  in diameter which are the anlagen of the branches of the internal iliac arteries are detected in prefetuses of this age group in the mesenchyma of the US, PMDs, MDs, however, they are not traced yet in the thickness of the walls of these structures.

An anlage of the corpus cavernosum penis and corpus spongiosum penis is identified in prefetuses of the male gender – 44.0-49.0 mm PCL. The crura of the penis are closely adjacent to the anlagen of the pubic bones. On both sides of the median sagittal plane one can identify vessels located among the anlagen of the pubic bones. An accumulation of vessels of a diverse diameter is detected in the region of the penial head a lumen with irregular outlines 82-88  $\mu\text{m}$  in diameter lined with a single layer epithelium and in some areas with the prismatic epithelium is identified in the spongy part of the urethra.

On the frontal sections of the urethra – 49.0-50.0 mm PCL one can identify an anlage of the external sphincter of the urethra which is represented by the mesenchymal cells of an elongated form according to the spherical shape of the urethra. However, some of the mesenchymal cells have a spiral-like direction. At this stage of the development the MD is reduced in the upper and middle portions. The diameter of the unreduced portion of the MD at the gonad level fluctuates from 60 to 64  $\mu\text{m}$ . The MD lumen is lined with the single - layer cuboidal epithelium in which cytoplasmic processes directed into the lumen of the ducts are detected. A circular layer of the mesenchymal cells with nuclei of an oval form are revealed in the lower portion of the MD outside, that should be regarded as the beginning of the formation of the deferent duct.

At the beginning of the 11<sup>th</sup> week of the intranterine development (prefetuses – 54.0-56.0 mm PCL) structural changes of the MDs take place and where two layers are clearly differentiated: internal, 32-34  $\mu\text{m}$  thick represented by one row of cylindrical cells and a more marked by thickness an external layer which is composed of cells of a predominantly oval form. At this stage of the development the urogenital sulcus is not evident yet.

The MD diameter increases above and below the neck of the urinary bladder in prefetuses of 58.0-62.0 mm PCL. The MDs thicken caudally, their cavities expand in a dorsolateral direction. A reduction of the PMDs occurs in prefetuses of the male

gender, with the exception of their united caudal portion that is a morphological substrate for the development of the prostatic sacculus that has no connection with the urethra. At the end of the 11<sup>th</sup> week of embryogenesis the MD lumen narrows somewhat both in a cranial and caudal direction and constitutes 40-42  $\mu\text{m}$ .

In fetuses, measuring 65.0-76.0 mm PCL the cavity of the urinary bladder exceeds the diameter of the urethral lumen almost 3 times. In a fetuses of the male gender – 65 mm PCL the transverse dimension of the cavity of the urinary bladder in its middle part makes up 1.65x2.3 mm and the corresponding dimension of the urethral lumen – 540x940  $\mu\text{m}$ . The neck of the urinary bladder dilates on the sides in a watering – can manner and resembles a sand-glass by its shape.

The pelvic part of the US transforms into the prostatic and intermediate part of the urethra. Simultaneously, there occurs an elongation of the genital eminence which is an anlage of the penis, while the urethral sulci take part in the formation of the lateral walls of the urethral sulcus. The latter extends along the caudal side of an elongated penis. The lumen of the prostatic part of the urethra noticeably narrows in a caudal direction and at the boundary with its perineal part its dimension equals 64  $\mu\text{m}$ . The glandular primordia of the prostate gland develop from the epithelium of the dorsal parts of the lateral walls of the urethra. At the level of the MD openings glandular primordia of the dorsal region of the prostate gland appear. At the end of the fetal period an increase of the dimensions of the prostatic sacculus is determined, predominantly, in a longitudinal direction, whereas its cavity almost disappears and is replaced by a cellular mass. In consequence of the development of connective tissue elements a thickening of the walls of the prostatic sacculus is observed.

### **Conclusions and prospects of further elaborations**

1. The formation of the urinary bladder and the prostatic part of the urethra as derivatives of the urinogenital sinus occurs in fetuses of 33.0-35.0 mm PCL.
2. Starting with fetuses of 42.0-46.0 mm PCL a more intensive organization of the layers of the urinary bladder is identified. Along with the processes of the proliferation of cells the phenomena of their differentiation are intensified, particularly in the superficial layers of the epithelium.
3. A considerable development of the smooth muscular elements is typical of fetuses, measuring 48.0-50.0 mm PCL that is accompanied with the formation of its internal sphincter muscle.

The research carried out by us as to establishing the terms of the formation of the urinary bladder and the urethra, the specific characteristics of their morphogenesis in fetuses is indicative of a demand for further ascertainment of correlations of the urinary bladder with the adjacent organs during the fetal period of human ontogenesis.

**Key words:** urethra, urogenital sinus, morphogenesis, fetus, human.

<sup>1</sup>A chair of Internal Medicine № 2, Vinnitsa Pirogov National Medical University. (Pirogov Street, 56. Vinnitsa, Ukraine 21018, E-mail: [admission@vsmu.vinnica.ua](mailto:admission@vsmu.vinnica.ua));

<sup>2</sup>Vinnitsa Autopsy Regional Office (Pirogov Street, 54. Vinnitsa, Ukraine 21018)

## **BONE TISSUE REMODELING OF THE LUMBAR SPINE IN COPD MODEL RATS ACCOMPANIED BY SEX HORMONES DEFICIENCY**

**Introduction.** The acceleration of osteoporosis formation can be expected in the presence of chronic inflammation, including the development of COPD. To consider that women have a higher prevalence of osteoporosis, experimental ovariectomized COPD model Wistar rats is of a scientific and a clinically relevant interest. Therefore, the *aim of this study* was to compare the structural and functional changes bone tissue of COPD model Wistar rats vs ovariectomized COPD model Wistar rats.

**Materials and methods.** It has been performed the study of 70 healthy female white Wistar rats. 25 COPD model rats were included to the first group [Pat. 50517 UA IPC G09B23/28 (2006.01)]; 25 ovariectomized COPD model rats were included to the second group. The control group consisted of 20 intact animals.

**Results.** Indices of bone tissue architecture of control group animals correlated to histological indices of the physiological regeneration process of lumbar vertebrae bone tissue.

The histological changes that indicate the remodeling/modeling processes ratio disorder of the lumbar vertebrae bone tissue which have revealed the resorption process have been detected in COPD animals within up to the 6th month of the study. Bone architecture disorders have been found to have a mixed (trabecular-cortical) type.

Pathological changes of physiological regeneration process disorder of lumbar vertebrae bone tissue in the 2<sup>nd</sup> group of animals have been shown to be similar to the changes of the 1<sup>st</sup> group of rats, but these ones were more intensive.

Compared to the previous period, within up to the 9th month of the study signs of pathological remodeling lumbar vertebrae bone tissue with a prevalence of bone resorption in COPD animals were a marked significant and accompanied by the onset of pathological fractures.

Bone tissue changes is found to reveal in ovariectomized COPD rats a decrease of bone remodeling processes with signs of mainly smooth resorption of bone tissue accompanied by mild osteoblastic reaction and general decrease of osteoplastic processes.

**Conclusions:** 1. Histopathological changes of the physiological regeneration process disorder of lumbar vertebrae bone tissue in ovariectomized COPD rats are similar to the changes of the COPD rats, but these ones are more intensive compared to the 1<sup>st</sup> group of animals. 2. Predominance of abnormal mixed type bone resorption, a significant architecture disorder, especially spongy bone tissue and composition, early osteoporosis formation, which is accompanied by the onset of pathological fractures, have enhanced due to estrogen deficiency and has a direct correlation to the followup duration of the study.

**Key words:** COPD, osteoporosis, ovariectomy.



© **Drachuk O.P.**

National Pirogov Memorial Medical University, Pharmacology department (Pirogov st., Vinnytsya, Ukraine, 21018, [drachukolga@gmail.com](mailto:drachukolga@gmail.com))

## **RESEARCH OF THE ANTIHYPOXIC ACTIVITY FOR SUCCINIC ACID DERIVATIVES IN CONDITIONS OF CIRCULATORY HYPOXIA IN RATS**

**Introduction.** Hypoxia plays the important role in the pathogenesis of the heart and lung diseases, poisonings, in conditions of the excessive physical activity etc. So the research of the new compounds with antihypoxic effect is one of the important tasks of the experimental pharmacology. We are directing our attention to the succinic acid derivatives: antilactate [malic acid and mono-[(2-dimethyl amino)ethyl ether] of succinic acid] and bemithyl succinate [2- ethylthyobenzimidazole succinate]. Our particular interest to these derivatives can be explained by important role of the succinic acid in cellular respiration. So in the present study our purpose was to study antihypoxic activity for the succinic acid derivatives antilactate and bemithyl succinate in conditions of circulatory hypoxia in rats.

**Materials and methods.** 50 rats weighing 180-220 g were divided into 5 groups: 1<sup>st</sup> - control rats, 2<sup>nd</sup> – rats, which received antilactate in the dose 5% from its LD<sub>50</sub> intraperitoneal, 3<sup>rd</sup> – rats, which received bemithyl succinate in the dose 5% from its LD<sub>50</sub> orally, 4<sup>th</sup> – rats, which received bemithyl in the dose 5% from its LD<sub>50</sub> intraperitoneal, 5<sup>th</sup> - rats, which received mexidolum in the dose 100 mg/kg intraperitoneal. It was used an experimental model of acute disorders of cerebral circulation (ADCC), which was modelled on the rats by bilateral ligation of the common carotid arteries. Antihypoxic action of researched compounds was estimated by the dynamic of mortality rate of rats with ADCC. The data were processed by methods of variation statistics.

**Results.** It was researched that the succinic acid derivatives antilactate [malic acid and mono-[(2-dimethyl amino)ethyl ether] of succinic acid] and bemithyl succinate [2- ethylthyobenzimidazole succinate] have antihypoxic (anti-ischemic) activity in conditions of circulatory hypoxia in rats. Antilactate was more effective in critical period of the experiment and has 9 times greater the duration of the protective effect than the mexidolum and 12 times greater the duration of the protective effect than the bemithyl. The researched compounds can be drawn up in a row according to the duration of their antihypoxic effect: Antilactate (43 mg/kg) > Mexidolum (100 mg/kg) ≥ Bemithyl succinate (69 mg/kg) > Bemithyl (29 mg/kg). The analysis of the compounds dosage showed that antilactate is two times more active, bemithyl succinate is nearly 1,5 time more active in antihypoxic activity than mexidolum.

**Conclusions:** The succinic acid derivatives antilactate and bemithyl succinate have antihypoxic activity in conditions of circulatory hypoxia in rats.

The succinic acid derivatives antilactate and bemithyl are interested for future researches their antihypoxic activities.

**Key words:** succinic acid, bemithyl, antilactate, mexidolum, hypoxia.

© **Hovda R.V.**

State Higher Educational Establishment «Ternopil I.Y. Horbachevsky State Medical University», Ternopil

## **STRUCTURAL CHANGES IN HUMERAL BONES OF ADAPTED TO EXTRACELLULAR DEHYDRATION RATS WITH DIFFERENT TYPES OF AUTONOMIC NERVOUS SYSTEM IN SEVERE EXTRACELLULAR DEHYDRATION**

**Introduction.** The investigation was conducted on adapted to extracellular dehydration white male rats with different types of autonomic nerve system status. We studied the morphological microscopic and submicroscopic changes of humeral bones of rat males at severe extracellular dehydration of organism. We founded quantitative characteristics of bone pathomorphosis of experimental animals and heir resistance to abiotic factor. This resistance depends from the type of the autonomic nervous system of animal. It is proved that bone tissue of humeral bones of white laboratory rats with parasympathetic type characterized by best adaptation parameters.

Somatic type (build body) is genetically determined feature of the whole organism [Nikityuk et al, 1998], and one of its numerous features are reactivity, expression of certain options of homeostasis reactions and types of adaptation in adverse environmental conditions. It reflects the relationship of body characteristics to specific functional states and predisposition to certain diseases [Agadjanyan et al, 2000].

As summarized morphological and functional characteristics of the individual, it includes features physique, mental activity, metabolism, autonomic, adaptive and pathological reactions. That determines the nature of exchange, morphology, functional status, regulation of body systems, i.e. specific of value influences of the autonomic nervous system (ANS) to body during the life and adaptation of the individual [Puzyrev et al, 1997; Pushina et al, 2004]. In addition to direct regulation of the functional activity of the internal organs, it provides global adaptive-trophic function of the organism [Volozhin et al, 1987], which ultimately governs the maintenance of homeostasis and processes of adaptation to changing environmental conditions.

Bone tissue is depots of minerals and is the stabilizer of the ionic composition of the internal environment [Verbovoy, 2001; Kryzhanovskyy et al, 2002]. It is an active member of homeostasis of the organism. This leads to significant changes in the organization of the bones in pathological processes. Therefore, among the problems of theoretical and clinical medicine is the need to regeneration of damaged mineralized tissues [Bumeyster, 2009]. The ensuring of effective solution of this problem has the access to experimental morphology and allows to investigate the

nature and dynamics of changes in the structure and function of bones under various environmental impacts to the body.

*The aim* of the work was to establish the differences in pathological changes of structural components of humeral bones at severe extracellular dehydration of adapted to dehydration experimental animals with different types of autonomic nervous system.

**Materials and Methods.** The experiment was conducted on 24 mature white male rats. Animals were kept in a vivarium with the bioethics requirements.

Three groups with different output type and functional tone of the autonomic nervous system were formed according to methods of variational pulsometry by Baevsky [Baevsky, 2004]. Each of groups includes 6 animals: the first group – animals with severe functional predominance of the sympathetic division of ANS, the second group – rats with predominance of functional influence of parasympathetic ANS; the third group – are formed by rats with a balanced influence of both ANS divisions. The fourth group served as a control. It was created by intact rats.

Experimental animals were subjected of 14 cycles of adaptation to isotonic dehydration during 42 days. Animals were feeding by demineralized products with the weakly concentrated solution of Lasix (within 2 days) and normal diet of vivarium (third day).

The rats received only demineralized products with the weakly concentrated solution of Lasix at the next stage, which continued during 90 days. The severe extracellular dehydration of organism was result of this diet (deficit of extracellular water more than 10%).

To study the structural and functional changes occurring in the humerus

We used osteometric methods of W. Duerst [Duerst, 1926], histological studies of tissue staining with hematoxylin and eosin and according to Van Gison, histomorphometrical measurement; material sampling and processing pieces of epiphyseal cartilage for submicroscopic studies carried out by conventional methods [Sarkisov 1996]. Sections were made with ultramikrotom LKB-3, contrasted and studied in the electron microscope TEM-125K. Statistical analysis of digital data [Lapach et al, 2000; Rebrova, 2000] performed using Excel 2007 and the software package "Statistica 6,0" (StatSoft, USA) on a personal computer Intel ® Core™ 2Duo.

**Results.** The researches of osteometric dates of the humeral bones of experimental animals of different groups indicate significant deviations from control values during severe extracellular dehydration.

We observed slightest changes in distal epiphysis width (up 7.32% in groups of normotonic and sympathotonic rats and 7.47% - in vagotonic). Width of the proximal epiphysis narrowed to 12.85%, the average length of humeri decreased 10,00-10,07%. This deficit is small. However, size of the bones of intact group increased on 6.57% for the width of epiphyses and 9.72% increase in the length during 90 days). That is why, the 1-3% reduction of sizes are indicators of active osteoklastic processes and smooth resorption which are present at severe dystrophic and atrophic changes in the tissue. Maximum mechanical deformation of bone occur in mid diaphysis when moving animals. Magnitude of losses transverse and anteroposterior

of sizes of diaphysis at compared with controls was 20,36-26,81%. These figures indirectly indicate extremely serious condition of long bone of experimental animals, but there are no statistically significant differences in osteometric indexes between groups of animals with different types of ANS ( $p > 0.05$ ).

The investigation of histological preparations of parts of experimental rats humeral bone during severe extracellular exsiccosis indicates a consistent development of structural pathology of different groups of experimental animals in our study, but we can say about considerable morphometric differences of pathological changes in the bones of experimental animals with different vegetative status.

The amount of stroma increases dramatically in the proximal epiphyseal cartilage of the humerus. The amount of cells greatly impoverished in the zone of indifferent cartilage, cell-free empty lacunae observed throughout the field of view. The upper edge of the plate, which borders with epiphysis of humerus heavily warped. The bone trabeculae dramatically thinned, sometimes touch to indifferent zone and form a cell with cellular elements of the bone marrow. The increased amount of intermediate substance displaces chondrocytes isogenic groups and replaces columns of chondrocytes in areas of reproduction and maturation. Most cells of cartilaginous plate are characterized by hydropic dystrophy phenomena. In the initial sections of the proliferative zone of cartilage are observed cells of destruction zone. This indicates about the discoordination processes of reproduction and differentiation of cartilage cells. The signs of severe balloon dystrophy are observed in majority cells cytoplasm.

Morphometric research of epiphyseal plate indicate a significant deceleration of linear rates of growth in all zones of cartilaginous plates and significant differences between groups with different types of ANS. Thus, the width of epiphyseal cartilage of normotensive rats less than control at 22.93%, which is 5.82% lower than in parasymphatotic rats, but is 11.90% greater than similar indices of symphyatotic rats. Proliferative zone is characterized by similar proportions of losing: the deficit size of the zone of normotonic animals was 52.38%, which is 8.69% less than in vagotonic and 20.20% better than symphyatotic group. The measuring of definitive cartilage zone is characterized by narrowing 52,87-53,03% in normo- and vagotonic groups relative to norm, and which 22,60-22,93% better than symphyatotic rat males. Electron microscopic research of epiphyseal cartilage tissue in proliferative zone detects changes that are similar in all groups of animals. Chondrocytes are characterized by signs of structural damage and functional impairment. Intercellular substance is optically light, immature, not structurally formed, poor in collagen fibrils.

Collagen elements disoriented relative to cellular structures. There are transitional forms that contain optically dense shriveled nucleuses and characterized by elongated oval shapes. The cytoplasm of these cells enlightened, poor in organelles with signs balloon and fatty degeneration. Granular endoplasmic reticulum and Golgi apparatus are fragmented. Endoplasmic cisterns are small and deformed. Number of ribosomes on the endoplasmic reticulum surface dramatically reduced, sometimes separate areas completely degranulated.

Effect of severe extracellular dehydration during a long time led to significant changes of compact substance of diaphysis of the humeral bone of experimental rats. Transformations are represented by multiple necrosis, dystrophic and atrophic changes that have affected the structure of compact substance of diaphysis.

Painting of complete destruction of bone structures are observed on transversal section of mid-diaphysis . The whole area of osteon zone are destroyed by numerous resorption fields and necrosis, which merge together to form a giant sekvester mass. Preserved bone tissue contains in itself contoured well defined cementation lines.

Prolonged exposure of severe abiotic factors initiated the distortions of normal processes of bone, destroyed the structure of compact substance, which is currently represented by amorphous bone tissue with numerous ossein fields. Areas of necrosis especially pronounced from endosteum side. Zone of external surrounding plates also destroyed. Externally it is covered by fibrous membrane of periosteum. Borders of osteon layer, zone of outer and inner surrounding plates can be distinguished rather approximately.

Such changes are characteristic of all experimental groups of white rats. The morphometric studies were hampered by the lack of clear boundaries between the studied elements. In many cases, the difference between the rates of control and experiment and between experimental groups was unreliable. This is shown in the diagram.

**Conclusions.** These research results are needed for further study of reparation of bony changes in organisms with different types of ANS and developing specific recommendations to prevent the negative effects of dehydration in the body and bone in particular.

**Key words:** bone, diaphysis, epiphysis, epiphyseal cartilage.

© **Liskina I.V., Kuzovkova S.D., Oleksynska O.A., Zagaba L.M.**

State Organization «National institute of phthiology and pulmonology named by F.G. Yanovsky National academy of medical sciences of Ukraine» (Director of the Institute – academician Y.I.Feschenko; Laboratory of pathomorphology, head of the laboratory – Liskina I.V., e-mail [liskina@ifp.kiev.ua](mailto:liskina@ifp.kiev.ua); 10, M. Amosova Street, Kyiv, UKRAINE, 03680; [admin@ifp.kiev.ua](mailto:admin@ifp.kiev.ua); [secretar@ifp.kiev.ua](mailto:secretar@ifp.kiev.ua))

## **MORPHOLOGICAL CHARACTERS OF THE LIPID METABOLISM DISREGULATION IN THE LUNG TISSUE IN PATIENTS WITH MULTIDRUG-RESISTANT FIBRO-CAVERNOUS TUBERCULOSIS**

**Introduction.** The global epidemic of tuberculosis which include Ukraine, the modern pathomorphosis of TB disease, the increasing worldwide incidence of multidrug-resistant tuberculosis (MDR-TB) cause more extended morphologic investigations of that pathology. Traditional histochemical methods not lose its

significance. There is no enough information about lipid metabolism disregulation in lung tissue at MDR-TB.

The aim of the present study was to elucidate peculiarities of accumulation and localization of lipids in lung tissue in chronic multidrug-resistant pulmonary tuberculosis with morphologically different activity of specific inflammation.

**Materials and methods.** The main group includes 15 cases of chronic fibro-cavernous TB with multidrug-resistant infect according to microbiologic data. This group divided into two subgroups based on the specific activity levels established by histological examination, 9 cases with high activity, 6 – with moderate activity. Investigation includes wall of cavern, pericavity areas of lung tissue and superficially normal tissue far from the macroscopic lesions. Control group forms 10 cases without tuberculosis lesion – histologically normal tissue of lung.

Histological samples were received by cryotome (Termo Shandon Ltd, Great Britain) at (13-15) ° C under zero. Staining performed by mixture of sudan III-IV. Localization of lipids was established by light microscopy. The conventional gradation of lipid droplets according to their diameter was used: micro-droplets (1–2 µm), small droplets (3–10 µm), and large droplets >10 µm.

**Results.** Lung tissues in control group were free from lipid droplets or have traces of lipids in bronchial epithelium.

Histological findings in fibro-cavernous TB. The next results were obtained.

**Table 1.** Accumulation of lipids in layers of chronic cavern wall when different activity levels in multidrug-resistant fibro-cavernous TB, number of observations (%)

Lipid droplets	Layers of chronic cavern wall		
	caseous necrotic	granulation	fibrous
High activity of fibro-cavernous TB (n = 9)			
diameter 1 – 2 µm	88,9 ± 10,5	66,7 ± 15,7	11,1 ± 10,5
diameter 3 – 10 µm	22,2 ± 13,9	66,7 ± 15,7	11,1 ± 10,5
diameter more than 10 µm	11,1 ± 10,5	22,2 ± 13,9	–
Moderate activity of fibro-cavernous TB (n = 6)			
diameter 1 – 2 µm	100,0 ± 0,0	66,7 ± 19,2	16,7 ± 15,2
diameter 3 – 10 µm	50,0 ± 20,4	83,3 ± 15,2	–
diameter more than 10 µm	–	33,3 ± 19,2	–

**Table 2.** Accumulation of lipids in lung tissue outside of cavern when different activity levels in multidrug-resistant fibro-cavernous TB, number of observations (%)

Lipid droplets	Area of examination in lung		
	pericavity zone	focuses of specific inflammation	visceral pleura
High activity of fibro-cavernous TB (n = 9)			
diameter 1 – 2 µm	11,1 ± 10,5	55,6 ± 16,6	44,4 ± 6,6
diameter 3 – 10 µm	22,2 ± 13,9	55,6 ± 16,6	33,3 ± 5,7
diameter more	33,3 ± 15,7	–	33,3 ± 5,7

than 10 $\mu\text{m}$			
Moderate activity of fibro-cavernous TB (n = 6)			
diameter 1 – 2 $\mu\text{m}$	16,7 $\pm$ 15,2	66,7 $\pm$ 19,2	50,0 $\pm$ 20,4
diameter 3 – 10 $\mu\text{m}$	16,7 $\pm$ 15,2	33,3 $\pm$ 19,2	33,3 $\pm$ 19,2
diameter more than 10 $\mu\text{m}$	66,7 $\pm$ 19,2	16,7 $\pm$ 15,2	16,7 $\pm$ 15,2

No statistically important differences in our data were received.

**Conclusion.** Our results suggest significant dysregulation of lipid metabolism in lung tissues in chronic fibro-cavernous TB independent from the activity level of specific inflammation.

Significant signs of lipid dystrophy reveals in structures of chronic cavern. In all cases in caseous layer of cavern diffuse accumulation lipid micro-droplets was observed. In granulation layer of cavern diffuse localization of micro-droplets and small droplets out to cells prevailed. Some of lipid droplets were in epithelioid macrophages. Minimum lipids were in fibrous layer of cavern.

Outside of cavern maximum lipid accumulation was in cytoplasm of alveolar macrophages.

The character and signs of lipid dystrophy in lung tissue are evidence of no adequate of plastic and reparative protective mechanisms during course of multidrug-resistant fibro-cavernous TB.

**Key words:** lipids, multidrug-resistant fibro-cavernous pulmonary tuberculosis, the morphological level of activity.

© Shevchuk T.I.

Vinnitsa National Pirogov Memorial Medical University, department of medical biology (21018, Ukraine, Vinnytsya, Pirogov str., 56, e-mail: [shevti@meta.ua](mailto:shevti@meta.ua))

## MORPHOLOGICAL CHANGES OF THE VASCULAR BED OF THE HEART IN EXPERIMENTAL DISLIPOPROTEIDEMIA AND ITS PHARMACOCORRECTION

**Introduction.** Ischemic heart trouble is the most widespread disease in the world. Many-sided nature of pathogeny of atherosclerosis requires application for treatment of many groups of medicinal facilities, that is why rational is the use of preparations with polytropic effect, such as Vinboron. Therefore study of morphological changes of coronal vessels of myocardium at experimental dislipoproteidemia and at the terms of correction pathological will become medicinal facilities with polytropic effect is actual.

**Materials and methods.** Conducted experiment on 28 crawls-males of breed "chinchilla" by mass 3,0-4,7 kg State of experimental dislipoproteidemia on classic methodology of M.M.Anichkov by feeding to the animals of cholesterol in a dose 0,5

gs/kg of body weight during the first 3 months. In next 30 days experimental animals were divided into such groups: 1 - the first group was laid down by intact animals that was subject to no influence, 2 groups are animals with experimental dislipoproteidemia without further treatment, 3, 4 and 5 groups on a background the modelled pathology got accordingly Vinboron (5 mg/kg), Pentoxifylline (5 mg/kg) and Vinpocetin (2 mg/kg) during a month. For further morphological research took away hearts. On transversal celloidine cuts investigated the intramural vessels of small caliber, determined the area of transversal cut of arteries, area of road clearance, external and internal diameter, thickness of wall and index of Vogenvort.

**Results.** At research of myocardium of animals with experimental dislipoproteidemia the typical atherosclerotic changes of coronal vessels, that narrow the road clearance of vessels, are educed, and sometimes there is complete obturation of their road clearance. Morphometric the increase of area of transversal cut of vessels is educed on a 56,22 %%, thickness of wall - on 73,44 %%, and also reduction to the area of road clearance on 48,68 %% and internal diameter of arteries - on 18,29 %% as compared to the group of intact animals.

Under the action of Vinboron the expressed tendency shows up to normalization of indexes of morphometric vessels. The area of transversal cut diminishes on a 30,41 %%, thickness of wall - on 31,97 %% and an internal diameter increases - on 7,01%% and accordingly the road clearance of arteries broadens on 50,03 %% as compared to the group of untreat animals.

In the group of animals that got a Pentoxiphylline, the area of road clearance of vessels increases a 47,09%%, area of wall diminishes on 17,54%%, and other indexes do not change as compared to animals with pathology.

Under the action of Vinpocetin for certain the area of road clearance of arteries and index of Vogenvort (accordingly on 45,00 %% and 39,34 %%) change only, other indexes small differ from the analogical indexes of group of crawls with an experimental model.

**Conclusion.** So, violation of lipid metabolism leads to expressed structural changes in the blood vessels of myocardium of experimental animals.

It was determined, that medicines can inhibit the progress of atherosclerosis medicinal facilities and stimulate recovery myocardium. Efficiency of the preparation more Viboron considerable than the preparations it was compared, namely: Pentoxiphylline and Vinpocetin.

These results suggest promising future of experimental and clinical study of Vinboron at ischemic and dystrophic processes in a heart on the background of dislipoproteidemia.

**Key words:** atherosclerosis, vessels, heart, pharmacocorection.

© Shkolnikov V.S.

Vinnitsa National Pirogov Memorial Medical University, Department of Human Anatomy (56 Pirogov st., Vinnitsa, Ukraine, 21018)



## MORPHOMETRIC PARAMETERS OF THE SPINAL CORD STRUCTURES OF HUMAN FETUSES AGED 14-15 WEEKS OF THE INTRAUTERINE DEVELOPMENT

**Introduction.** In recent years a considerable progress has been achieved in terms of genetic and molecular programs determining the development and differentiation of neurons. At the same time a lot of issues remain open especially during determination of histotopography of the spinal cord neuron complexes at early stages of the prenatal period of human ontogenesis.

Thus, the *objective* of this scientific research is determination of the spinal cord morphometric parameters of fetuses aged 14-15 weeks of the ontogenesis intrauterine development and namely of the segment longitudinal and cross dimensions, areas of the grey and white matter, and neuron groups of grey matter.

**Materials and methods.** The anatomic, histological and morphometric examination of the spinal cord of human fetuses aged 14-15 weeks of the intrauterine development was performed. There were no CNS maldevelopments. The digital data received during the research process were processed statistically.

**Results.** Groups of motor neurons could be clearly observed in the grey matter within the boundaries of future anterior horns at the level of cervical segments  $C_6 - C_7$  and they formed the following nuclei: anteromedian and anterolateral, posteromedian and posterolateral. The anterior horn nuclei were of a polygonal form. The area of the anteromedian nucleus made up  $0,013 \pm 0,004 \text{ mm}^2$ , anterolateral -  $0,032 \pm 0,006 \text{ mm}^2$ . The area of the posteromedian nucleus made up  $0,011 \pm 0,003 \text{ mm}^2$ , posterolateral -  $0,026 \pm 0,003 \text{ mm}^2$ .

Groups of large motor neurons could be clearly observed in the grey matter within the boundaries of future anterior horns at the level of thoracic segments  $Th_6 - Th_7$ , and they formed the anteromedian and anterolateral nuclei, which area made up  $0,016 \pm 0,003 \text{ mm}^2$  and  $0,011 \pm 0,005 \text{ mm}^2$  respectively. The anterior horn nuclei were of a polygonal form.

Accumulation of small associative neurons could be observed within the boundaries of future lateral horns. There was Clarke's nucleus with the area of  $0,022 \pm 0,003 \text{ mm}^2$  located between the base of the posterior horns and the posterior grey commissure at the distance of  $27,4 \pm 2,8 \text{ }\mu\text{m}$  from the central canal that was well marked in the lower thoracic segments.

Groups of motor neurons could be clearly observed in the grey matter within the boundaries of future anterior horns at the level of lumbar segments  $L_3 - L_4$  that formed the following nuclei: ventromedial and ventrolateral, dorsolateral and dorsomedial. The boundaries of the anterior horn nuclei looked like ellipsis. The area of the anteromedian nucleus made up  $0,007 \pm 0,001 \text{ mm}^2$ , anterolateral -  $0,015 \pm 0,002 \text{ mm}^2$ . The area of the posteromedian nucleus made up  $0,004 \pm 0,001 \text{ mm}^2$ , posterolateral -  $0,017 \pm 0,003 \text{ mm}^2$ . Clarke's nucleus was relatively non-marked and was represented on the average by three-four associative neurons. A large accumulation of sensory neurons and mostly microglia cells could be observed within the boundaries of the posterior horns that corresponded to I-III Rexed laminae of a

middle-aged person.

Groups of motor neurons could be clearly observed in the grey matter at the level of sacral segments  $S_2 - S_3$  within the boundaries of future anterior horns and they formed the following nuclei: anteromedian and anterolateral, posteromedian and posterolateral. The posterolateral nucleus was of elongated ellipsoid form, the rest of the forms of the anterior horn nuclei were similar to spherical. The area of the anteromedian nucleus made up  $0,005 \pm 0,001 \text{ mm}^2$ , anterolateral -  $0,006 \pm 0,002 \text{ mm}^2$ . The area of the posteromedian nucleus made up  $0,007 \pm 0,001 \text{ mm}^2$ , posterolateral -  $0,018 \pm 0,002 \text{ mm}^2$ .

**Conclusions.** 1. All the neuron complexes of the anterior horns could be clearly observed in both halves of the segment on the specimen of the spinal cord of the human fetus aged 14-15 weeks of the intrauterine development. The groups of motor neurons located in the lateral position, excluding the anterolateral nuclei of the thoracic segments, occupied the largest area.

2. Lateral horns were relatively mildly marked in the upper thoracic segments and were clearly determined starting with  $Th_{10}$  and ending with  $L_2$ . Clarke's nucleus was relatively better marked at the level of segments  $Th_6 - Th_{12}$ . Clarke's nucleus was represented by three-four associative neurons at the level of lumbar segments.

3. An insignificant asymmetry has been revealed in the sizes of the area and linear dimensions between the right and left halves of the spinal cord segments. The largest area of the grey matter could be observed in the cervical segments, the least - in the thoracic segments. The largest area of the white matter could be also observed in the cervical segments and the least - at the level of sacral segments.

**Key words:** morphometric parameters, spinal cord, grey matter, white matter.

© **Smiukha O.A.**

Department of Operative Surgery and Topographic Anatomy of Vinnytsia National Pyrogov Memorial Medical University (Vinnytsia, Pyrogov street, 56, 21018, Ukraine)

## **SUBMICROSCOPIC CHANGES IN STRUCTURAL COMPONENTS OF THE TESTICLE AT VARICOCELE MODELING**

**Introduction.** Varicocele, being one of unfavorable prognostic factors of male infertility, is a cause of great changes in spermogram from oligospermia to azoospermia [Nikiforov, Bachuryn, 2009; Fylyonenko, Babushkin, 2012; Zylbersztejn et al., 2013]. Till present days, the main method to study the pathogenesis of male infertility remains a morphological method, combined with clinical data allows to diagnose somatic and sexual condition of a patient and to choose a treatment method. Upon varicocele, there is the development of the pathological process in structural components of the testicle (called "varicose orhopatiya"), which has a direct negative effect on the germinative testicle function (Kondakov et al, 2000).

*Purpose* of the study: to determinate submicroscopic changes in structural components of the testicle at varicocele modeling.

**Material and methods.** Experimental studies conducted on ten mongrel male dogs, weighing from 9 to 12 kg. there was received the permit of Commission for Bioethics of Vinnytsia National Pyrogov Memorial Medical University (Minutes №1 dated January 13, 2011) to conduct experiment, which established that the studies meet ethical, moral and legal requirements according to Ministry of Public health of Ukraine №281 dated 01.11.2000. While conducting the study, we followed the basic rules of proper laboratory practice GLP (1981), Law of Ukraine №3447-IV „About protection of animals from cruelty” of February 21, 2006. The dogs were divided into control and experimental groups. Tn the control group of animals, any intervention for two mongrel dogs (control 1) did not performed, three animals (control 2) had opening of abdominal cavity performed under thiopental anesthesia, then there was lamellar closure of abdominal wall and after 30 days there were performed dissection and closure of the left inguinal canal. The animals of the experimental group (five dogs) were created varicocele model. There was performed no intervention after creating varicocele model. Varicocele modeling was performed on mongrel male dogs. Gonadotropinum of 300 U / kg and 0.2 ml of 1% Progesteronum solution parenteral injected daily for 10-days. The surgery was on the next day. Midline laparotomy performed, and a ligature was applied to the left renal vein at 2/3 of its diameter at the point between the inferior vena and testicular veins. The bougie inserted through the renal vein damaged valves of testicular vein. The wound was sutured up in layers. After 30 days of study both testicles were examed.

**Results.** Conducted electron microscopy testes of testicles in the control group of animals showed that Sertoli cells sustentocytes and spermatogonias are on the basement wall membrane of seminiferous tubules.

Submicroscopic study of the testes of animals in modeling varicocele showed that all the structural components of the body significantly change. The nucleus of myoid cells have the oblong shape in wall of convoluted seminiferous tubules, but their karyolemma makes numerous invaginations. In cell cytoplasm, myofibrils and mitochondria, lysosomes are partially damaged. Irregularly thickened basement membrane appears swollen, illuminated and has unclear contour. There is a destruction of supporting cells. Some of them have osmiophil karyo- and cytoplasm. Nucleuses changed pycnotic with invaginations of karyolemma and focal dilated perinuclear spaces. The destruction of organelles discovered, the tubules of endoplasmic reticulum significantly are enlarged in some areas, and create light cavities of irregularly shape. Damaged mitochondrias have electronic transparent matrix, reduced cristas. Cytoplasmic processes are thinning, they also have destruction of organelles.

There is also damage of spermatogenic epithelium. Detected damaged spermatogonias have pycnotic nucleus with invaginations of caryolemma and unstructured cytoplasm. Most spermatocytes 1<sup>st</sup> order have swollen cytoplasm with illuminated sections. Their karyolemma has unclear contour. Cytoplasm of spermatocyte 1<sup>st</sup> and 2<sup>nd</sup> order has vacuoles of different sizes, damaged mitochondrias with round inclusions with osmiofilic border. Intercellular spaces delited.

Characteristic for part of spermatids is acrosome defectives, disturbance of plasma and nuclear membranes, karyoplasm looks homogeneous.

There was also discovered severe destruction of part of sperm cells. Their head is reduced significantly with osmophilic pycnotic nucleus. Perinuclear cytoplasm is thickened also and has no structure. There are electron light zones around live sperm cells, and groups of cells dip into sustentocytes cytoplasm (it is possibility that they are phagocytized for recycling). Blood capillaries of the interstium depending on their section area have different lumens, but they always contain blood corpuscles, mainly erythrocytes. Disorder of basement membrane borders. Endotheliocyte nucleus have round and oval form, but they contain a lot of heterochromatin, which forms osmophilic areas, mainly near karyolemma. Cytoplasm of Endotheliocyte has irregular thickness and swollen illuminated areas without organelles.

Nucleus of Leydig cells are reduced, with irregular shape and have electron thickened heterochromatin areas in karyoplasm. The cytoplasm contains electron light, swollen, structureless areas, lipid inclusion of large osmophilic located groups. Small mitochondria have homogeneous matrix with cristae contoured unclear. Thus, the analysis of the discovered results showed that at varicocele there are changes of convoluted seminiferous tubules testicles is changing, depression of Leydig cells, injury of interstitial and connective tissue of testicle.

**Conclusions and prospects for further development.** Experimental varicocele showed that there are significant changes in all structural components of testicle in the gonads of animals. 1. Destruction of supporting cells occurred in pycnotic modified nucleus, destruction of organelles. 2. Damage of spermatogenic epithelium characterized by injury of spermatogonia, spermatocyte 1st and 2nd order. 3. Leydig cells changed their shape, had small nucleus, light, swollen, structureless areas of cytoplasm, injured mitochondria. 4. Discovered severe destruction of sperm cells.

**Key words:** varicocele, modeling, testicle, electron microscopy.

## ANTHROPOLOGICAL ARTICLE

© Soleyko O.V.

Department of Internal Medicine №2, Vinnytsia National Pyrogov Memorial Medical University (56 Pyrogov street, Vinnytsia, Ukraine, 21018)

### COMPLEX REHABILITATIONS OF PATIENTS WITH COMPLICATED COURSE OF POSTINFARCTION CARDIOSCLEROSIS

**Introduction.** The real problem of introduction of physical rehabilitation in daily clinical treatment practice of patients with postinfarction cardiosclerosis is the extremely many-sided. On the one hand, fast development of insufficiency of blood circulation, high lethality, poor quality of life, negative attitude to people around are featured for such clinically serious contingent of patients. From the other hand - numerous researches [Kiilavory et al., 1999] have proved that physical trainings of

the patients suffered from myocardial infarction through raising the tolerance to physical load improve metabolic processes in myocardium, increase the maximum oxygen consumption by a cardiac muscle, reduce myocardium need in the last one and contribute oxygen saving because of reduction of internal heart performance, increasing stroke volume, decreasing lactate content in blood. Besides, the scientific researches of the last years [Бобров и соавт., 2001] proved that there are many similarities between two conditions - insufficiency of blood circulation and detraining of myocardium. One of the important directions in development of problems for rehabilitation of patients with postinfarction atherosclerosis is research of influence of individual features of the patient to optimum rates of activation. Clinical features of a disease (recurrent myocardial infarction, existence of arterial hypertension, complication by chronic aneurism of heart, etc.) cause significant variability of activation rates for such patients. However, we did not meet the scientific works devoted to development of actions of complex rehabilitation for patients with the complicated course of postinfarction atherosclerosis and scale criteria of efficiency of rehabilitation for such patients. Marked changes of geometry and geometry and left-ventricular contractile ability in these patients are among the leading reasons of blood circulation insufficiency, which causes a significant decreasing in life quality and steady loss disability.

However, growing successes in conservative treatment of acute myocardial infarction for the last 10 years, early improvement of blood circulation of heart attack zone lead to preservation of areas of satisfactory vascularity even in aneurismal wall [Белов и соавт., 2002] where significant amount of viable muscle tissue preserved, which is one of favorable factors in favor of recovery processes of contractile ability of myocardium.

This problem is very actual one due to the improvement of treatment methods of acute myocardial infarction; there is a possibility of rehabilitation of patients with the complicated course of postinfarction atherosclerosis. Such patients need complex (drug and non-drug) rehabilitation actions. Regarding this fact, successful combination of physical training regime and medical correction intended for basic level of loading program optimization is possible at sanatorium stage of rehabilitation.

The *purpose* of our study was development and studying of complex rehabilitation efficiency of patients with complicated course of postinfarction atherosclerosis at a stage of sanatorium treatment.

**Materials and Methods.** There were examined 86 patients of age from 36 to 67 suffered from postinfarction atherosclerosis complicated with chronic postinfarction heart aneurism (ССРНА), who were on treatment in rehabilitation department of sanatorium "Khmilnyk" in Vinnytsia region. The III functional class (FC) of NYHA heart insufficiency was defined in most of patients (90 % of patients). Verification of the diagnosis of ССРНА was carried out on the basis of the international standard criteria [Борисов и соавт., 2002], all of patients on presanatorium stage was made coronography. The first control group was made of 42 patients receiving traditional therapy of blood circulation insufficiency (APF inhibitors,  $\beta$ - adrenoblockers, diuretics, digoxin, nitrates, antiaggregants). The second group included 44 patients

who received Mildronate in a dose of 1,0 g per day (two times a day) and Verospiron in a dose of 50 mg one time in the morning within 3 weeks staying in sanatorium as a part of complex therapy of the main disease. Activization of patients of both groups was according to 1 stage of the protocol of physical activities "Progressive walking" [Kavanagh et al., 1996] which included: training frequency - 5 times a week, distance - 10 km a week, speed of movement - 1 km per 13 minutes. Patients of both groups before their inclusion into study within 60 days were in stable condition (fluctuations of body weight no more than 0,5 kg). All patients before they were diagnosed myocardial infarction complicated with CCPHA, worked by profession in full.

Clinical, laboratory and instrumental examination was done in full at the beginning of complex rehabilitation program and at the end of the third week of stay in sanatorium. As a control of efficiency of rehabilitation actions, there was analyzed dynamics of disease clinical symptoms, the main indices of haemodynamics - heart rate, arterial pressure, Holter electrocardiographic monitoring, echocardiography by standard methods [Бобров и соавт., 2001]. There were calculated indices of body weight, measuring gastrocnemius muscle diameter, analyzed indicators of 6-minute walk test. Statistical processing of the results was performed by variation statistician methods using test of the Student and the Newman-Keuls. Distinctions at  $p < 0,05$  considered as reliable ones.

### **Results of the study and their discussion**

The prescription of the last myocardial infarction at admission of a patient to rehabilitation department was  $2,34 \pm 1,7$  years in average in patients of both groups. Duration of ischemic heart disease till of a transmural infarction caused to CCPHA formation made was from couple of hours to 6 years in patients of both groups, in average  $1,68 \pm 1,6$  years. The average FC of angina pectoris in the 1 group made  $2,98 \pm 0,12$ , in the 2nd -  $2,87 \pm 0,11$ . The average ejection fraction in the 1 group made  $43,6 \pm 3,4$  %, in the 2nd -  $42,9 \pm 3,1$  %.

As for the injury of coronary arteries by data of coronarography in patients of both groups, the most marked occlusive process was observed in anterior interventricular artery and in posterior interventricular branch of the right coronary artery.

The injury of proximal part of major coronary artery were observed in the majority of (81,48 %) cases. As for coronary occlusion, the maximal frequency of injury was observed in posterolateral branch of the circumflex artery - 80 patients (92,59 %). The second and the third place belonged, respectively, posterior interventricular artery - 41 patient (48,15 %) and posterolateral branch of the circumflex artery - 34 patients (40,74 %). The average number of affected arteries in patients of the 1 and the 2 group did not significantly differ and respectively made  $2,56 \pm 0,32$  and  $2,71 \pm 0,34$ . Thus, severity of coronary atherosclerosis (number of stenotic coronary arteries, stenosis rate) in both groups was average identical and correlate with T-dominant character of ST segment elevation by Holter monitoring data.

Accompanying pathology in patients of both groups by percentage composition did not differ significantly and was presented with hypertension, diabetes, chronic calculous cholecystitis.

While 3-week rehabilitation course, health significantly improved in all examined patients: decreased dyspnea, number of angina pectoris, there was a subjective

impression of increasing endurance of physical activities. . However, these changes were accompanied by improving test with 6-minute walking only in patients in the 2 group . The maximum distance which the patient passed in 6 minutes increased from  $301 \pm 17$  to  $467 \pm 32$  m ( $p < 0,05$ ). Among the patients of the 1 control group of 11 patients avoided the protocol of physical trainings (irregular performance, disorder in duration of training schedule). The maximum distance according to 6-minute walking test among these 11 patients made  $326 \pm 13$  m compared to the initial  $304 \pm 15$  pm. Among other patients of the 1 group who followed the protocol "Progressive walking" there were registered only the tendency to increasing the load volume, increasing maximum distance in 6-minute walk test from  $386 \pm 28$  m. Only the patients of the 2 groups for 3 weeks of comprehensive rehabilitation decreased body weight index from  $23.7 \pm 1.6$  to  $22.2 \pm 1.5$  ( $p < 0.05$ ), first of all, at the expense of reduction of fat thickness at level of the umbilicus from  $3,9 \pm 0,7$  cm to  $2,1 \pm 1,3$  cm. Loss of weight is one of processes, which defines a condition of cross-striated muscles. Its loss more than 10 % brings to clinically significant reduction of the maximum oxygen consumption that is decreasing in maximum effort and progressing of functional insufficiency. In patients with initially low values of body weight (less than 90% of ideal) while load performing, there wasn't detected decreasing body weight. Thus, the regular physical activities do not lead to cachexia progressing, and correct body weight of a patient at the expense of reduction of fat content and increasing of muscular weight.

Studying of peripheral muscle work [Hornig et al., 1996] in patients with insufficiency of blood circulation revealed that their condition may be connected with two processes - dysfunction and weight loss. Regular physical training leads to increasing of blood-flow volume in muscle group which is subject to be trained [European Heart Failure Training Group, 1998]. Dysfunction of cross-striated muscles is caused by reducing of active capillaries quantity in unit of volume; forming mainly anaerobic way of energy generation. In the basis of modern approaches to the optimization of the energy exchange in myocardium at ischemia and reperfusion is "switching" of ATF resynthesis from fatty acid metabolism to glucose metabolism that allows to increase the use of oxygen for the energy generation and, respectively, economic cardiac performance [Parker, 1995]. As the structural analog of natural  $\gamma$ -butyrobetaine metabolite, Mildronate modulates fatty acids by decrease endogenous carnitine biosynthesis and its concentration in myocardium, slows down the transferring of activated forms of long-chain fatty acids through cell membranes and preventing the accumulation of surface active metabolites in cell. This process inhibits oxidation of free fatty acids and activates alternative mechanisms of energy supply - glicolysis and the Krebs cycle [Kirimoto et al., 1996].

Besides, it is known that Mildronate help to improve the conditions of oxygen transportation at the expense of influence on ligandny spectrum of hemoglobin, mechanical resistance of erythrocytes and rheological blood properties [Skarda et al., 1997]. Specific effect of the drug is able to increase tolerance of organism tissue to hypoxia, especially kidney tissue, brain and skeletal muscle, their hypoperfusion determinates clinical symptoms of blood circulation insufficiency [Wolff et al., 2002]. The patients of the 2 group showed the bigger tolerance to physical activity,

the lower intensity of unpleasant subjective feelings comparing to the patients of control group because of stimulating effect of Mildranate on extracardiac compensation mechanisms of hemodynamic disorders.

Another important problem of cross-stripped muscle dysfunction is fibrosis progressing, caused significant increasing collagen synthesis. In the basis of fibrosis formation is stimulation of fibroblasts with aldosterone which overly synthesized in patients with insufficiency of blood circulation. At excessive amount of collagen, a muscular bundle moves from capillary that makes worse its nutrition and leads to functional insufficiency of a muscle. Thus, Verospiron, taken by the patients of the 2 group caused to improvement of capillary nutrition and respectively, to optimization of physical training. At cellular level functional insufficiency of a muscle is characterized by mitochondrion restructuring. The above-mentioned processes occur, primarily, because of impossibility to develop sufficient effort. Kiilavori K. i co-authors [Kiilavori et al., 1999] established that maximum effort of cross-stripped muscles in a patient with blood circulation insufficiency of III-IV FC in 2,8 times less, than a healthy person has, so the index of maximum effort developed by cross-stripped muscles, is reverse proportional to FC of blood circulation insufficiency, and feeling tired in the patient with blood circulation insufficiency during performing dosed physical load directly correlates with stage of muscle functional insufficiency. As a result of complex rehabilitation program the diameter of gastrocnemius muscle increased from  $33,9 \pm 2,3$  cm to  $36,8 \pm 3,1$  cm ( $p < 0,05$ ) only in patients of the 2 group. E. Hambrecht [Hambrecht, 1995] found that 24-week training provides significant increasing of blood flow volume in gastrocnemius muscles, maximum oxygen consumption, that is maximum developed effort. Biopsy of gastrocnemius muscle showed that training results in recovering of impaired mitochondrial architectonics. Dynamics of clinical finding, morphometric indices and physical endurance responded changes in echocardiographic data which characterized contractile function of the heart. Significant ( $< 0,05$ ) increasing of indices of heart contractile function observed in the patients of the 2 group compare to initial indices and control group. So, at the end of 3 week of treatment in rehabilitation department ejection fraction size was  $51 \pm 4,5\%$  in the 2 group compare to the 1st -  $44,7 \pm 3,6\%$  ( $p < 0,05$ ), that was respectively accompanied by decreasing FC insufficiency of blood circulation in patients of the 2 groups.

Safety of protocol implementation is proved by results of Holter monitoring: physical activities did not lead to increasing of number of cardiac rhythm disturbance. The other way, there were decreasing of heart rate and liquidation of rhythm variability, increasing of ST depression depth from 2 mm to 1 mm against the background of regular physical load. Duration and frequency of painless ischemia according to daily Holter monitoring decreased on the average for 71 % ( $p < 0,05$ ).

Thereby, the sanatorium stage of treatment is a good opportunity as to start physical rehabilitations of the patients with the complicated course of postinfarction cardiosclerosis, and successful combination of physical load requiem and drug correction. The offered scheme of complex rehabilitation of such patients at this stage of treatment effective and safe; all patients of the 2 group met the first stage of physical load regime appropriately according to the protocol "Progressive walking".



At the moment of the termination of stay period at rehabilitation department, the scheme of gradual load increase was developed for all patients of the 2 group according to the protocol at the out-patient stage, including physical training by the first stage for another 3 weeks and changing to the second stage (6 weeks) - gradual increase distance to 21 km week, speed of movement of 1 km in 11,5 minutes agrees the first stage. In case of bad physical load tolerance during this term patients are recommended to return to the first stage regime which is necessary to adhere for life. In case of good physical load tolerance within 16 weeks - lifelong keeping up of the offered regime.

**Conclusions.** 1. Using of the offered scheme of complex rehabilitation of patients with complicated course of postinfarction cardiosclerosis at a stage of sanatorium treatment help to sufficient improving myocardium contractile ability and physical load tolerance in the patients, overcoming myocardium detraining, decreasing duration and frequency of painless ischemia, downgrading functional class of blood circulation insufficiency and angina pectoris. 2. Continuation of complex rehabilitation at the next stages of the program will help to improve further forecast and global life index of such patients.

**Key words:** postinfarction cardiosclerosis, rehabilitation.

© **Novikov V.M.**

Poltava, Ukraine

## **CHANGES OF ELECTROMYOGRAM PARAMETERS OF MASTICATORY MUSCLES OF PATIENTS WITH DEFORMING FORM WITH DYSFUNCTIONAL DISORDERS TMJ AND DETERMINISTIC OCCLUSION VIOLATIONS**

**Introduction.** The aim - to improve efficiency of diagnosis and treatment of patients with deterministic disturbances occlusion and functional structures of the tooth-jaw system rheumatoid origin justification by orthopedic methods in complex treatment method of studying the functional relationships and metabolism; raising disclosure mechanism of pathological changes in tissues and prosthetic fields in the body based on clinical observations, laboratory and morphological studies.

**Materials and Methods.** There were observed 3561 patients, including 230 patients with occlusion violations against rheumatoid lesions of TMJ during the study of the period at rheumatological department of Poltava Regional Hospital.

For treatment, patients were selected from active rheumatoid 0 and process have been divided into five clinical groups of 9 people each, aged 30 to 60 years: 1 - patients with rheumatoid arthritis in the phase of activity; 2 - patients with rheumatoid arthritis in remission; 3 - patients with sclerotic arthrosis; 4 - patients with deforming arthrosis; 5 - patients with musculo-articular dysfunction.

**Results.** The article presents the results of electromyographic examination of patients with rheumatoid lesions, one of the most common chronic pathological conditions.

Along with this, there is very little information on rheumatoid lesions of the maxillofacial region.

For electromyographic recordings characteristic fuzzy segmentation structure for periods of rest and activity in the early stages of treatment. In periods of peace were recorded abnormal spontaneous bursts of activity that gradually disappeared within a month of treatment. Form bursts of activity was altered in the majority - the shape that mimics a triangle, with a gradual start activity and a sharp transition to peace. A characteristic feature of some bursts in time for the first month of treatment was the lack of a clear beginning and its end activity. Symptom occurred "miotatychnoyi delay" on the side. Changes bursts of activity in the form of balance of payments side during treatment were similar in shape, symmetrical in time, but much smaller in amplitude and saturation bursts of activity on the working side.

**Conclusions.** 1. There are bilateral and symmetrical lesions of muscle fibers in the early stages of the disease.

2. After a brief period of functional overload began braking processes increased bioelectrical activity that was triggered adaptation process.

3. The average increase in the amplitude of bursts to the control group, reducing the duration of the chewing cycle and periods of rest in terms of 3 to 6 months is typical electromyographic signs correctly chosen complex treatment of patients.

4. Therefore, electromyography of masticatory muscles allows features to fix their state in various forms of functional changes or diseases of the teeth-jaw system.

**Key words:** rheumatoid lesions of TMJ, electromyography, masticatory muscles.

© **Saldan J.Y.**

Vinnytsia M.I. Pirogov Memorial National Medical University, Department of Ophthalmic Diseases (46 Pirogov St., Vinnytsia, Ukraine, 21018)

## **DIAGNOSTICAL IMPORTANCE OF SPECTRAL OPTICAL COHERENCE TOMOGRAPHY IN CORNEAL DISEASES**

**Introduction.** This study represents the capabilities of the anterior eye part spectral optical coherence tomography (SOCT) technique for diagnostics and dynamic supervision over condition of patients with various degenerative and inflammatory diseases of the cornea.

**Materials and methods.** Observed were 85 patients aged 19 to 68 with the following pathological changes in the cornea: 23 patients (23 eyes) had corneal foreign bodies, 16 patients (16 eyes) had traumatic keratitis, 13 patients (13 eyes) had corneal ulcers, 9 patients (9 eyes) had post-surgery corneal edema, 8 patients (16 eyes) had dry keratoconjunctivitis, 9 patients (12 eyes) had corneal opacity of various intensity, and 7 patients (14 eyes) had congenital corneal dystrophy. The control group consisted of twenty 16 -70 year-old subjects (40 eyes) without corneal pathology with the normal visual function. In cases of unilateral disease, SOCT was performed on second intact eye. The study was conducted with the use of SOCT Copernicus spectral optical

coherence tomography unit produced by Optopol Technology. The study protocol is an A-strix, linear, and three-dimensional image.

SOCT technique made it possible to determine exact depth and size of foreign bodies in 23 patients (23 eyes); an increase in corneal thickness varying from 623 to 898 microns evidenced the presence of perifocal inflammation in these patients. Corneal thickness in the affected area of 16 patients (16 eyes) with a diagnosis of traumatic keratitis varied from 661 to 801 microns. 5 cases of traumatic keratitis revealed local detachment of posterior limiting membrane varying within the range of 43 to 54 microns. This explained the long duration of corneal edema with mild clinical symptoms of inflammation. The patients with corneal ulcers (13 patients, 13 eyes) at different stages of the pathological process demonstrated clearly visible progressive edge of ulcer, as well as the depth of ulcer and intensity of edema. SOCT data collected from patients with persistent postoperative corneal edema (9 patients, 9 eyes) have shown different sizes of posterior limiting membrane detachment and lack of connection of the corneal lesion rear segments.

In patients with corneal leukoma, the opacity area was presented as an area with a high optical density. The superficial cuts in patients with dry keratoconjunctivitis featured expressed irregularity. The patients with epithelial-endothelial dystrophy revealed cornea watering and formation of cysts of various sizes and numbers (from 51 to 62 microns) under the epithelium, the average corneal thickness was 863 microns; they also presented posterior limiting membrane detachment of different sizes.

SOCT has made possible to clearly differentiate the corneal layer with localized pathological process, and reliably (qualitatively and quantitatively) determine the morphological status of cornea integral parts.

**Key words:** spectral optical coherence tomography, diseases of the cornea.

© **Prevar A.P**

Vinnitsa National Pirogov Memorial Medical University, Department of General Surgery (56 Pirogov st., Vinnitsa, 21018 Ukraine)

## **CURRENT ASPECTS IN THE TREATMENT OF SEPTIC WOUNDS OF SOFT TISSUES**

**Introduction.** Restoration of the microvasculature in the inflamed area is one of the important elements of its healing. The *objective* of our research was to determine the condition of the local microcirculation in the patients with pyoinflammatory processes of soft tissues.

**Materials and methods.** 25 patients with acute pyoinflammatory processes of soft tissues aged from 18 to 58 years, divided into 2 representative groups were examined. The main group consisted of 9 patients whose drug complex included 10% of the actovegin solution by intravenous drop-by-drop administration on 0,9% NaCl

solution (250 ml) once a day. A daily dose of actovegin made up 1000 mg. The control group - 16 patients were treated according to the standard program. The microcirculation was examined by the method of photoplethysmography using a laser complex during hospitalization and on the 10th day of treatment.

### Results.

*Table 1* Blood filling level ( $M \pm m$ ).

Groups of patients	Inflammation epicenter		Inflammation limit		Out of the inflammation limit		Control point (symmetric body area)	
	Before treatment	After treatment	Before treatment	After treatment	Before treatment	After treatment	Before treatment	After treatment
main	25,43 ±4,4	19,24±2 ,46	13,14± 1,54	15,17± 1,87	11,47± 1,34	12,85± 1,54	11,87± 1,44	13,45± 1,85
control	24,12 ±3,89	16,23±2 ,12	13,56± 1,46	12,57± 1,87	12,03± 1,23	10,2±1 ,43	11,35± 1,36	11,88± 1,67

Note:  $p < 0,05$

*Table 2.* Dynamics of the wound process behavior.

Groups of patients	Wound process phases (day, $M \pm m$ )			Bed-day
	Necrolysis	Granulation appearance	Epithelialization appearance	
Main	3,86±1,46	5,35±1,56	7,88±1,77	11,86±2,34
Control	5,76±1,38	7,53±1,78	11,2±1,84	16,8±2,23

Note:  $p < 0,05$ .

**Conclusions.** 1. Microcirculation disorders can be observed in the inflamed area that negatively influence its clinical course. 2. The research results have shown the efficiency of using photoplethysmographic methods for research of the condition of the local microcirculation and evaluation of its correction. 3. For treatment of pyoinflammatory diseases it is recommended to include the drugs improving microcirculation.

**Key words:** pyoinflammatory diseases, microcirculation, photoplethysmography.

© Savoluk S.I.

Vinnytsia National N.I. Pirogov Memorial Medical University, department of surgery №2 (Vinnytsia, Ukraine)

**OBJECTIVITY EVALUATION OF INITIAL WEIGHT OF THE PATIENTS WITH NONCANCER OBSTRUCTIVE JAUNDICE IN THE CHOICE OF TACTIC SURGICAL TREATMENT**

**Introduction.** The poor results in the early postoperative period, due to tactical errors as a result of unjustified expansion of indications to the one-stage or radical interventions, which is accompanied by the increase in the number of complications due to a mismatch of the volume of operations the initial severity of patients. The aim of the work: on the basis of the evaluation of predictive ability of metabolic markers and their combination in the calculated indices to develop a practical and an indicative system of objective assessment of the initial severity of condition of patients with noncancer obstructive jaundice, complicated by acute hepatic failure, for selecting the optimum tactics of surgical solutions.

**Materials and methods.** Under observation there were 510 patients to assess the impact of conservative and operative treatment. The material for laboratory studies were venous and capillary blood. Changes determined at the time of admission, after pre-operative preparation, on 1, 3, 5, 7, 9, 12, 15, 18 postoperative day within 9 syndromes: CC3B, of, antioxidant imbalance cytopathic hypoxia, endothelial dysfunction, functional status of the liver, endotoxemia, lipid and carbohydrate metabolism (62 indicator, 10 indices).

**Results.** 21 metabolic predictors of complications are found in patients with noncancer obstructive jaundice (acute hepatic failure): general bilirubin, fibrinogen, IL-1, IL-6, IL-10, malondialdehyde, cholesterol, catalase, Central Bank, трансферрин, гомоцистеин, general protein, the total concentration of albumin, the effective concentration of albumin, ornithine carbamoyl transferase, glucose, HbA1c, average mass molecules, sorption capacity of red blood cells, high density lipoproteins, low density lipoproteins. On the basis of the anamnesis, clinical data and the results of laboratory and instrumental studies established prognostic scoring scale preoperative assessment of the risk of postoperative health complications. The use of scale allowed to form a category of patients, on the basis of the conditions to the implementation of a radical interventions to define the choice of surgical tactics that led to the reduction of the number of одноэтапных radical interventions with 63,84% to 48,4% increase in the number of patients for a landmark tactics with 36,15% to 51,6%, to reduce postoperative complications with 16,87% to 6,61%, postdecompression hepatic insufficiency with 10,84% to 1,65%, mortality from 7,23% to 0,83%. The redistribution of the structure of the interventions in favor of minimally invasive compensation determined the reduction of complications of laparotomic operations with 13,24% to 2,44%, purulent-septic complications with 7,83% to 1,65%, relaparotomy with 6,63% to 0,83%.

**Conclusions.** For screening diagnostics of weight of acute hepatic failure at patients with noncancer obstructive jaundice it is necessary to be guided by the general bilirubin and criteria of their gradation on groups: 1) level to 50  $\mu\text{mol/l}$  – the compensated stage of hepatic dysfunction, a latent stage of acute hepatic failure; 2) 51-100  $\mu\text{mol/l}$  – the subcompensated stage of hepatic dysfunction, easy degree of acute hepatic failure; 3) 101-200  $\mu\text{mol/l}$  – a stage of a decompensation of hepatic dysfunction, moderate severity of acute hepatic failure; 4) more than 201  $\mu\text{mol/l}$  – a terminal stage of renal dysfunction, heavy degree of acute hepatic failure. For correction of supresivny violations of a stage of immunodefect into structure of obligatory methods of preoperative inspection of patients with obturatsionny

jaundices of not tumoral etiology has to enter immunogram. The structure of screening laboratory methods for such patients has to be expanded at the expense of EKA and HbA1c and their use in settlement indexes as they objectively reflect extent of all metabolic violations and efficiency of perioperatsionny conservative actions. For an assessment of preoperative risk of postoperative complications it is necessary to use a mark scale, stating weight of a condition and forming groups of patients with definition of indications to radical and landmark interventions and methods of their sparing realization, considering their postoperative safety.

**Key words:** obstructive jaundice, choice of a treatment tactic, prognosis of treatment development, diagnostics, preventive measures against postoperative complications.

© Slepchenko N.S.

Vinnitsa National Medical University n.a. M.I. Pirogov, Chair of Propedeutics of Internal Medicine (Address: Khmelnytsky highway, 96, Vinnitsa, Ukraine, 21029, [slepchenko77@mail.ru](mailto:slepchenko77@mail.ru))

## **SMOKING TOBACCO AMONG ADOLESCENTS AND ITS INFLUENCE ON THE FORMING OF ASTHENIC SYNDROME**

**Introduction.** Smoking is one of the most dangerous impairment of the health life in all over the world. Smoking promotes occurrence and progression of the respiratory and cardiovascular diseases, it has negative impact on the emotional sphere. Smoking also may leads to worsening of course of gastrointestinal, dermatological diseases. It increases risk of the occurrence of malignant tumors. Moreover, it is regarded that smoking may form vegetative disorders, it may make the people asthenic and impair adaptive mechanisms.

The goal of the study was to estimate the pattern of the prevalence and intensity of the smoking among the persons of 13-16 years old and its influence on the forming of asthenic syndrome.

**Materials and methods.** 837 schoolchildren of 13 and 16 years old were enrolled into the study. They completed specially designed questionnaire. The measurement of the degree of smoking was performed using the scale of L.D. Malkova and adopted by T.G. Chernova on the basis of clinical and psychological observations and well-known questionnaire MMPI. The status of the smoking was estimated using the Fagerstrome's test.

The statistical processing includes the calculation of the relative and average values as well as mean error for them. Analysis of the reliability of the differences between the values was held by the materiality criterion differences. The estimation of the t was performed with using of classical table of Student's criterion.

**Results.** The prevalence of smoking is sufficiently higher among the 16-years old adolescents versus this value in group of 13-years old children (24,2% vs 12,9%) . There is a higher prevalence of smoking both among the male and female in 16-years

old persons in comparison of group of 13-years old persons. The 13-years old children began to smoke at the age of 9,8 years. The 16-years old persons started to smoke when they were 11,9 years. The regularity of smoking was formed at the age of 11,8 years in group of 13-years old children and it was formed at the age of 14,5 years among the 16-years old persons. Thus, the habit of smoking was formed during the 1,9 years in 13-years respondents and it was formed during 2,5 years in 16-years old respondents.

The 53,7% persons of 13-years old respondents and 44,5% persons of 16-years old persons consider that smoking indicates the psychological discomfort and internal psychological problems.

The main part of respondents answered that fight against smoking is necessary but its intensity is not high enough. This part was 40,3% in group of 13-years old and it was 42,6% in group of 16-years old among the 16-years old.

Prevalence of asthenic syndrome is higher in case of smoking (48,4% vs 25,6%,  $p < 0,001$  ). The moderate correlation was find out between the smoking and manifestation of the asthenic syndrome ( $Q=0,48$ ).

**Conclusions.** 1. It was estimated that every seventh person smokes among the 13-years old children and every fourth person smokes among the 16-years old adolescents. The quantity of smoking girls rises from year to year. 2. Smoking changes from marker of psychological discomfort into the habit. 3. Smoking influences on the frequency of the occurrence of asthenic syndrome. This fact is especially well-seeing in girls.

**Key words:** smoking of tobacco, epidemiology, asthenic complex of symptoms.

© **Baralo R.P.**

Vinnica State named after M.I.Pyrogov Medical University, Department of clinical pharmacy and clinical pharmacology (Pyrogova str., 56, Vinnitsa, 21000, Ukraine)

## **ANTIBACTERIAL THERAPY FOR COMPLICATED UROLITHIASIS**

Purpose of research was study the condition of antibiotic prophylaxis and antibiotic therapy in patient's with complicated urolithiasis in urology departmen of Pirogov regional hospital.

**Material and methods.** Was conduction of analysis tactics treatment of patient's with urolithiasis in urology departmen of Pirogov regional hospital in Vinnica on the first quarter 2012. Was estimated of 64 medical history of patient's (16 men and 48 woman's). All patient's taced the antibiotics for antibiotic prophylaxis and/or antibiotic therapy by exacerbation of inflammatory process. All patient's was split up into two groups. In first group (17 patient's) - kidney stone move away without surgical intervention, second groups (47 patient's) - kidney stone was removed by means of different metods of surgical intervention.

**Results.** The Cefalosporins of II – III generation's and the fluoroquinolones of II – III – IV generation's was prescribe most often among other antibiotics.

Only 3 patient's (17,6%) with first group has exacerbation of the pyelonephritis when the kidney stone move away. These patient's taked combined antibiotics therapy by help of two antibiotics – the Cefalosporins of III generation in injection form and the fluoroquinolones of II – III generation's per os. The course of treatment was didn't more than 10 days. Another 14 patient's for the purpose of the prophylaxis of the pyelonephritis taked antibiotic monotherapy per os – aminopenicillins, or fluoroquinolones, or Cefalosporins (to choose). The course of treatment was to 5-6 days. The stent procedure of kidney was more frequent (34, 04%) among of the patient's second groups. Discovered following characteristic prescription of the antibiotics from second groups patient's: 1. the patient's more frequently taked combined antibiotics therapy; 2. The Cefalosporins of III - IV generation's and the fluoroquinolones of III – IV generation's was prescribe most often to combined antibiotics therapy; 3. the drugs taked in parenteral dosing; 4. The courses of antibiotics therapy lasted for 7- 12days. On the outpatients stage the patient's second groups continued the antibiotics therapy per os to 7-10 days. The choice antibiotics was – nitrofurans, the cefalosporins of II generation, the fluoroquinolones of II generation, aminopenicilin's grup of antibiotics.

**Conclusion.** By appointment of antibiotics was taked into account the weight of disease, opportunity lesions of the urogenital tract by microbial association, which to be able to meet today in 30% and more patient's. The doctor's prescribe the combined parenteral antibiotics therapy are provide the broadening action spectrum of antibiotics (ability to act on enable microbial association), quick achievement of the therapeutic concentration of antibiotics in nidus of infection. If microorganism's maintain the sensitivity to choose antibiotic the positive treatment outcome was provided.

Study change of the pharmacokinetic parameters antibiotics with prescribe in given patient, such as  $MIC_{90\%}$  give a possibility discover the growth of the resistant flora in time.

© **Belik N.V.**

Vinnitsya National Pirogov Memorial Medical University, Department of the Normal Physiology (Pirogov str. 56, Vinnitsya, Ukraine, 21018)

## **MODELING THE CARDIOINTERVALOGRAPHY INDICES IN WOMEN AND MEN WITH THE EUKINETIC TYPE OF HEMODYNAMICS BY THE METHOD OF INCREMENTAL REGRESSION ANALYSIS**

**Introduction.** In spite of the great amount of the scientific researches dedicated to physiological and clinical interpretation of the cardiointervalography (CIG) indices up to the present the large-scale population investigations which are needed for



standard-setting of the cardiac rate variability (CRV) for different age and sex categories of practically healthy people were not conducted in the world.

*The purpose* of the research was modeling by the method of incremental regression analysis the normative cardiointervalography indices in healthy men and women of the first mature age with the eukinetic type of hemodynamics depending on the anthropometric and somatotypological parameters.

**Materials and methods.** Results of the anthropometric examinations after Bunak method [1941], determination of the somatotype components after J. Carter and B. Heath [1990] method, component body mass composition after the methods of J. Matiegka [1921] and American Nutrition Institute [Heymsfield, 1982], the CIG indices of 36 men and 65 women with the eukinetic type of hemodynamics were taken from the database of the university subjects materials “Development of the normative health criteria of the different age and sex population groups on the basis of the anthropogenetic and physiological organism characteristics examination with the aim to determine the markers of multifactorial diseases”.

Rheovasographic and cardiointervalographic investigations were carried out by means of the cardiological computer diagnostic complex.

The regression models of the normative cardiointervalography indices were made in the standard package “STATISTICA 6.1” (belonged to VNMU Research Center, license № BXXR901E246022FA). To make the regression models the CIG indices used in clinic practice were taken.

**Results.** It has been set that in women of the first mature age with the eukinetic type of hemodynamics the only CIG index – the power in the range of low frequencies – depends on the total complex of the anthropometric and somatotypological parameters of the organism more than on 50 % (RI=0,546). Regressive polynomial was made for this index. The other CIG indices in the women depend on the anthropometric and somatotypological signs less than by 50% – the coefficients of determination are from 0,116 to 0,474, the mathematical modeling of these indices was not conducted accordingly.

In men of the first mature age with the eukinetic type of hemodynamics seven from nine CIG indices depend on the anthropometric and somatotypological parameters more than on 50 % – the coefficients of determination are from 0,577 to 0,751 (RI from 0,577 to 0,751). The got regression equations include more often: cephalometric parameters (24,4 %), girth sizes (19,5 %), long bones distal epiphyses width (14,6 %) and body diameters (12,2 %).

**Conclusion.** The made mathematical models will let individualize the normative magnitudes of the CIG indices.

**Key words:** mathematical modeling, cardiointervalography, eukinetic type of hemodynamics, anthropo-somatotypological parameters.

Vinnitsya National Pirogov Memorial Medical University (Pirogov str. 56, Vinnitsya, 21018, Ukraine)

## **RATIONALE FOR COMPREHENSIVE APPROACH TO TREATMENT OF DISTAL OCCLUSION WITH UNDERLYING IMPAIRED NASAL BREATHING**

**Introduction.** Our studies, as evidenced by the results of anthropometric, extra- and intraoral examination of patients, confirm the change in tonus of masticatory and facial muscles that influence the appearance of a patient. These findings are considered the grounds for rationale for comprehensive approach to treatment of distal occlusion.

Distal occlusion is one of the most common pathologies accounting for 28.4-46.6% of total dental-facial anomalies. This pathology, that often affects vital functions (chewing, swallowing, and speech) and changes the appearance of patients, is often resulting from mouth breathing and accompanied with a variety of muscle weakness syndromes.

*The aim* of our study was to substantiate holistic approach to treatment of patients with distal occlusion and mouth breathing not only by establishing extra- and intra-oral signs, but also by examining functions of facial and masticatory muscles.

**Materials and Methods.** In the study we examined sixty three 9-12 year-old patients with distal occlusion and mouth breathing. We evaluated appearance of patients, performed intraoral examination, and anthropometric evaluation of plaster jaw models. Traditionally we evaluated surface electromyographic activity of the muscles and defined "silence period" and "masseter-reflex".

**Results.** The results of medical examination demonstrated expressed clinical signs - changes in posture in 44 (69%) patients, visually apparent diminishment of the lower third of the face, the apparent weakness of lips, protruded chin, and deep supraperiosteal line. 59 (93%) patients demonstrated not closing mouth, parted lips, marked adenoid-type face.

**Results of intra-oral examination:** 26 (41%) of 63 patients had abnormalities of frenulum attachment. 42 (66%) patients had vestibular position of crowns, and 21 (33%) of them had oral position; 20 (31%) patients revealed diastema and trema; deep incisal overlap was observed in 17 (26%) of them. Large and small occlusion keys did not match. 35 (55%) patients reported infantile swallowing or deglutitive problem, and speech disorder was observed in 23 (36%) subjects.

**Results of anthropometric examination:**

58 (92%) patients had narrowed upper jaw, 3 (4%) patients had expansion of the upper jaw, and 2 (3%) patients had size of the jaws within the normal range; 42 (67%) patients presented protruded anterior segment of dentition, shortened one was diagnosed in 21 (33%) subjects. 49 (78%) patients had Grade 1 (within 39-42%) and Grade 2 (within 32-39%) narrowed apical base of upper jaw. The narrowed lower jaw apical base Grade 1 was within 38-41% and Grade 2 was within 34-38%.

**Electromyographic examination:**

In 21 patients, in phase of functional rest, we discovered voluntary activity of temporal muscles with peaks from 0.12 to 1.08 mV in masseter muscles and from

0.11 to 1.32 mV in temporal muscles. Patients of the study group demonstrated overloaded temporal muscles compared to chewing ones. The maximum bioelectrical activity was lower by 17 - 25.3% for masseter muscles and higher by 26.3 - 31.9% for the temporal ones.

**Table 1.** ECG parameters of muscles of patients with distal occlusion and abnormal breathing.

Masseter muscle	Ta, s	Tc, s	k	Amp max, mV	Amp mean, mV	Tean max	Tean mean
m.masseter dex.	0,243	0,201	1,21	0,31	0,30	310,3	297,2
m.masseter sin.	0,242	0,203	1,19	0,31	0,30	311,0	298,7
m.temporalis dex	0,273	0,208	1,31	0,63	0,57	319,1	312,2
m.temporales sin	0,274	0,208	1,32	0,61	0,56	322,1	309,7
m.orbicularis oris	0,343	0,286	1,2	0,31	0,3	242,1	235,3

**Table 2.** Time indicators of masseter reflex and the "silence period" by study groups and standards.

Masseter muscle	Masseter reflex in II clinical group	Normal masseter reflex	Silence period in II clinical group	Normal silence period
m.masseter dex.	6,2-8,2	6,0-7,4	9,1-9,7	8,2-9,0
m.masseter sin.	6,2-8,4	6,0-7,4	9,1-9,9	8,2-9,0

**Conclusions.** Thus, the clinical examination methods, (extra-oral and intra-oral) showed severe clinical signs, reduced muscle tonus, and in particular, of the circular mouth muscle, in 59 (93%) study subjects; the electromyographic examination confirmed changes in muscle tonus. These findings confirm the necessity of treatment of distal occlusion with underlying impaired muscles and mandatory regulation of muscle function and normalization of breathing, along with introduction of new techniques and new methods of treatment.

**Key words:** distal occlusion, mouth breathing, extra- and intraoral signs, muscle tonus.

© **Palamarchuk O.V.**

Pharmacology Department of Vinnytsia National Pirogov Memorial Medical University (56 Pyrohova St., Vinnytsia, Ukraine, 21018)

## **BIORYTHMOLOGIC PECULIARITIES OF MEDICAL CONDITION OF FIRST-YEAR STUDENTS AND THEIR INFLUENCE ON SUCCESS IN LEARNING PROCESS**

Introduction. The criteria of integrated functional status of 16-17-year-old adolescent students have been established and scientifically substantiated, as well as their

biorhythms and temperament have been identified in terms of their further use for monitoring the influence of health status on successful progress in education.

The researches and studies performed by scientists in recent decades suggest that human health and the ability for intellectual, creative and physical labor, and harmonious perception of the world depends largely on how the regime of work and rest corresponds to individual human biorhythms. Knowledge of biological rhythms is important for practical human activity, especially in the field of medicine and ergonomics. Taking into account the biological rhythms, one can choose the most favorable period in the state of the human body for therapeutic effect, get maximum training effect and forecast changes in the biological system. Therefore, the important task is to develop the principles and models of selective diagnosis and correction of boundary conditions with due regard to individual psychological characteristics of adolescents, and effective teaching healthy lifestyle to the above target group. [N.S.Smirnov et al., 2010].

*The aim* of our study was exploration of biorythmologic features of first-year students and their temperament in order to determine the type of their work capacity for education process.

**Materials and methods.** The subjects of the study were first-year students of pharmaceutical faculty, the psycho-physical characteristics of functional state of which were assessed using the Ostberg test for determining biorhythms and Eysenck test for evaluation of temperament type.

**Results.** According to the international classification of biorhythmologic types by Ostberg, the Swedish scientist, all people belong to one of three major groups: active in morning time - "larks", active in evening time - "owls" and intermediate — "doves". According to the results of students questionnaire survey, we found that the dominated type of work capacity among adolescent students was a morning one - 41%, while the evening type was inherent to 33%. Arrhythmic subjects with intermediate type of work capacity account only to 26% of students. The differences in individual students were also found according to Eysenck scale. The "larks" were energetical young people with a choleric-type temperament. They demonstrated the greatest efficiency and activity in the morning time. The "owls" were also proactive, but in contrast to morning type subjects they easily forgot all failures and emotional problems; their type of temperament was melancholic. Arrhythmic subjects, "pigeons" featured both sanguine and phlegmatic temperament type and occupied an intermediate position between the above two groups of students, but still were closest to those the morning type. Among first-year students, the dominated temperament was "choleric" - 41%, "melancholic" and "sanguine" were common for 28% and 23% accordingly, and "phlegmatic" was inherent to only 8% of subjects.

**Conclusion.** Taking into account the above said, the temperament of students depends on the type of biorhythm and the age of adolescents. Differences in the work capacity rhythm that characterize representatives of morning and evening groups are caused by specific hormonal and mental peculiarities of subjects that may be either incorporated in their genetic code or formed during lifetime.

**Key words:** biorhythmology, temperament, first-year students, educational process, healthy way of life.

© Bilyakov A.N.

National Medical University named after O.O. Bogomolets, Department of Forensic medicine (st. Oranzhereina 9, Kyiv, Ukraine, 04112, [andrey@mibilex.com.ua](mailto:andrey@mibilex.com.ua))

## DIAGNOSTIC CRITERIA OF CHOLESTEROL CONTENT IN HUMAN ADRENAL TISSUE FOR MEASURING THE DURATION OF A LETHAL TRAUMA

**Introduction.** Due to their increased synthesis of corticosteroids and catecholamines human adrenal glands play the key role in stabilization of homeostasis rates in case of the development of a stress reaction.

Having generalized the results of research carried out by lots of scientists, the following conclusion can be drawn: their morphofunctional state changes depending on the cause of death and the duration of dying. This is an evidence to the fact that the amount of hormones synthesized at the stress reaction changes and the leading place among them belongs to a glucocorticoid, cortisol.

Glucocorticoids are synthesized from their precursor substance, i.e. cholesterol, at the inner mitochondrion membrane, that is a speed-limiting reaction influenced by plenty of factors. That is why cholesterol balance can change depending on the cause of death and the duration of dying.

*The objective* of our work was to establish the diagnostic criteria of the quantitative content of cholesterol (membrane and free) in human adrenal tissue to determine the duration of a lethal injury at an early stage of antemortem period.

**Materials and methods.** Samples of adrenal tissue were extracted from corpses of persons who had died due to the influence of traumatic factors. They were divided into groups according to the duration of the trauma. The control group included persons whose death had been caused by a chronic and acute ischemic heart disease. Cholesterol was studied using thin-layer chromatography with Sorbifil plates. The quantitative content was estimated with the help of an in-house developed software and a patented method (useful model patent No. 54582 registered on 10.11.2010) that assesses the area of a substance patch being investigated automatically based on the chromatogram after it is scanned and compared with the patch area of the standard.

In general 40 tests were conducted, 30 of which were used to estimate the content of cholesterol (membrane and free) in case of violent deaths and 10 tests were made using the tissues of the persons who had died due to ischemic heart disease.

**Results.** The results of estimating the cholesterol content in adrenal tissues of the persons who have died as a result of a trauma of different duration as well as diagnostic criteria for determining the duration of a lethal mechanical trauma are represented in Table 1.

**Table 1.** The results of estimating the cholesterol content in adrenal tissues of the persons who have died as a result of a trauma of different duration as well as diagnostic criteria for determining the duration of a lethal mechanical trauma.

No.	Cause of death	Duration of dying	n	Cholesterol mcg /100 mg of dry tissue $\bar{X} \pm x$	p	$M \pm 2\sigma$
1	Ischemic heart disease	Sudden (short term) death Control	10	406±38	P1-P2 > 0.05 P1-P3 < 0.001 P1-P4 > 0.05	166-646
2	Traumatic injuries	Immediately after the trauma	10	500±30	P2-P3 < 0.01 P2-P4 < 0.05	306-694
3	Traumatic injuries	Within a short time period after the trauma	10	670±45	P3-P4 < 0.001	390-950
4	Traumatic injuries	1 or 2 hours after the trauma	10	400±34		188-612

**Conclusions.** It is found out that the content of cholesterol in adrenal tissue of the persons who died within different periods of time after an injury in the range 694 to 950 mcg/100 mg of dry tissue means that death occurred within a short period of time (from several to some tens of minutes). The content more than 646 mcg/100 mg of dry tissue shows that death occurred immediately after the lethal factor influence or some tens of minutes later but it could not have taken place 1 or 2 hours after the injury.

**Key words:** cholesterol, lethal trauma, diagnostic criteria, duration of a trauma.

© **Bobrova I.A.**

SI "Institute of Epidemiology and Infectious Diseases im.L.V.Hromashevskoho NAMS Ukraine" (vul.Amosova, 5, Kiev, 03038, Ukraine)

## **VALUES OF PROINFLAMMATORY CYTOKINES IN PATIENTS WITH CYTOKINE-ASSOCIATED THYROPATHY MANIFESTATION ON HEPATITIS C**

**Introduction.** The course and consequences of diseases infectious nature, including hepatitis C, much depends on the immune reactivity of patients, with the main role belongs immune dysfunction that are leading pathogenesis.

**Objective:** to examine the contents of proinflammatory cytokines - IL-1 $\beta$  and IL-6 in patients with thyroid pathology development during antiviral treatment of chronic hepatitis C.

**Materials and methods.** In the period from 2005 to 2011 examined 294 patients with chronic hepatitis C, including 178 men and 116 women.

All surveyed received a course of combined antiviral therapy (PVT) according to standard regimens lasting from 24 to 48 weeks depending on the genotype of the virus. The control group comprised 68 healthy donors suspended. The content of IL-1 $\beta$  was determined kits "A-8766", "IL-1beta-ELISA-BEST", IL-6 were determined set reagentov "A-8768", "IL-6 ELISA-BEST2" to quantify their levels (JSC "Vector Best", Novosibirsk) according to the manufacturer's instructions.

**Results.** Investigation of proinflammatory cytokines in relatively healthy donors revealed that the average IL-1  $\beta$  is  $1,6 \pm 1,14$  pg / ml in healthy people the level of serum interleukin and plasma is less than 11 pg / ml. The average concentration of the other studied cytokine IL-6 in relatively healthy donors was  $2,0 \pm 1,0$  pg/ml, maximal in no case exceeded 10 pg/ml.

In the examined patients with chronic hepatitis C before the CIT without antiviral therapy increase IL-1 $\beta$  more > 11 pg / ml observed in 11 patients, and 28 people in the group were absent and equal to "0".

**Conclusions.** The amounts of proinflammatory cytokines IL-1 $\beta$  and IL-6 were studied dynamically during antiviral therapy in patients with cytokine-associated thyropathy on hepatitis C. The trends of their changes in depending condition of thyroid gland were found.

**Key words:** cytokine-associated thyropathy, hepatitis C, cytokines, IL-1 $\beta$ , IL-6.

© **Bodnar A.B.**

Bukovina State Medical University

## **CHARACTERISTIC OF MICROECOLOGICAL STATE COLON IN CHILDREN WITH CONGENITAL PATHOLOGY OF THE COLON**

**Introduction.** It is known that microorganisms coexist with man as complex multicomponent communities - microbiocenosis, form a kind of ecosystem with many symbiotic relationships. The total number of microorganisms that live in different habitats of the human body, is 10<sup>15</sup>, which is 2 orders of magnitude greater number of their own cells microorganism.

The density of bacteria in different parts of the gastrointestinal tract (GIT) is different.

**Objective:** to study the microbiological condition of the colon cavities in children with congenital disorders of the intestine.

**Materials and methods.** The study was conducted in 66 pediatric patients aged 4 to 15 years with congenital disorders of the colon (dolihsyhma, dolihokolon,

mehadolihosyhma, mehadolihokolon). The control group consisted of 40 children. Evaluated the clinical manifestations of intestinal dysbiosis and state abdominal colon microflora.

**Results.** E. coli most of facultative anaerobic and aerobic bacteria flora that normally always leads to stimulation of immune reactivity in general and in particular in the gut due to the continuous antigenic stimulation as systemic and local immunity. However, with a decrease in population and increasing protective properties of autochthonous obligate anaerobic microflora concentration in Escherichia biotope increases, showing a number of pathogenic properties. With increasing populations of E. coli in the body of the child in infectious and inflammatory diseases these organisms alone or in association with other opportunistic microorganisms play a leading role etiological factor. In our view, the traditional hiperotsinka role in the functioning of Escherichia coli normobiotsenozi insufficiently substantiated. E. coli artificial increase population levels can cause serious infectious complications. Numerous observations indicate that intestinal microbiota aerobic component, especially Escherichia a population level, able to recover on their own after a qualitative and quantitative normalization of bifidobacteria and lactobacilli.

**Conclusions.** The study found that most children with congenital forms of colon intestinal dysbiosis I-IV degree, which requires a differentiated use of conservative treatment, such as decontamination of pathogenic and conditionally pathogenic enterobacteria and other microorganisms, as well as the correction of species composition and microflora population level.

**Key words:** children, microbiocenosis, colon.

© Chayka V.G., Muntian L.M.

Vinnitsa National Pirogov Memorial Medical University, Department of Dental Orthopedics (56 Pirogov st., Vinnitsa, 21018 Ukraine)

## **DESCRIPTION OF THE DYNAMICS OF CHANGE OF THE CHEWING PRESSURE FORCE IN TOTALLY EDENTULOUS PATIENTS WITH REMOVABLE PROSTHESIS WITH DAMPENING PROPERTIES**

**Introduction.** At present the urgent problem of the dental orthopedics is increase of the functional efficiency of complete removable prostheses and improvement of the patients' adaptation thereto. A majority of removable prostheses in the clinical practice are produced with a rigid, more rarely with a two-layer basis that is conditioned by the simplicity of production and less prime cost. But these constructions do not always provide positive treatment results especially under unfavourable anatomico-topographical conditions of the prosthetic bed (Beziazychnaya N.V., 2006).

Due to this fact it became necessary to produce such kinds of prostheses that could solve the problem of tolerant co-existence of the basis with the prosthetic bed tissues



during the adaptation process and further use of the prosthesis.

The research *objective* was to study the dynamics of change of the chewing pressure force on treatment of totally edentulous patients with removable laminar prostheses with dampening properties.

**Materials and methods.** We treated 37 totally edentulous patients with removable laminar prostheses with dampening properties of own construction. According to certain clinical conditions while producing removable prostheses we examined the conditions of prosthetic beds and namely: we determined the severity degrees of alveolar bones and mucosa atrophy, detected and considered unfavourable factors for fixation and stabilization of prostheses, took into account the differentiated mucosa compressibility in various areas of the prosthetic bed, studied the chewing pressure.

**Results.** The mucosa condition according to Suppli was determined while treating the patients. The first class of the mucosa according to Suppli was revealed in 13,3% of totally edentulous patients only on the upper jaw. The second mucosa class according to Suppli was observed more often on the upper and lower jaws, 53,3% and 57,1% respectively. The share of patients having upper edentulous jaws with the 3rd mucosa class of the prosthetic bed was 33,4%, the similar index prevailed on the lower edentulous jaws – 14,3%. 28,6% of the patients were diagnosed the 4th class of the prosthetic bed on lower jaws, at the same time there were no signs of the 4th class on the upper jaws of the patients from this group. Generally, the mucosa compressibility of the alveolar bone vestibular area of the upper jaw depending on the measurement location did not differ ( $P>0,05$ ), at the same time a significantly larger mucosa compressibility was revealed in the front area on the lower jaw ( $P<0,05$ ). The mucosa compressibility of the alveolar bone oral area of the upper and lower jaw was the same ( $P>0,05$ ). The examination of the mucosa compressibility of the hard palate areas made it possible to learn that the mucosa of the rear area had the largest compressibility ( $0,61\pm 0,01$ ) mm that was significantly more ( $P<0,05$ ) than in the front area ( $0,40\pm 0,01$ ) mm and in the area of the palatine suture ( $0,30\pm 0,02$ ) mm.

The largest absolute values of the mucosa compressibility among the patients of the examined group ranged from ( $0,61\pm 0,01$ ) mm up to ( $0,94\pm 0,01$ ) mm, and the lowest - ( $0,30\pm 0,02$ ) mm. We've determined that the compressibility of soft tissues in the alveolar bone area depends on their atrophy. The lowest compressibility values show the areas requiring relief during the functional imprint.

When using the prostheses with a rigid basis the chewing pressure of the front area of the denture was  $2,77\pm 0,15$  kg and of the right lateral denture area –  $3,51\pm 0,28$  kg, of the left -  $3,48\pm 0,23$  kg. After the use of complete removable laminar prostheses with dampening properties the chewing pressure of the denture front area made up  $3,11\pm 0,17$  kg and of the right and left lateral denture area -  $4,13\pm 0,30$  kg and  $4,12\pm 0,24$  kg respectively ( $P<0,05$ ).

**Conclusions and prospects of further developments.** 1. Increase of the chewing pressure registered in the patients was accompanied by its even distribution on the denture lateral areas. 2. The dampening layer did not only "equalize" the indices of the chewing pressure in the denture symmetrical areas but also contributed to almost twofold growth of the chewing pressure in the lateral areas as compared to the front area.

**Key words:** dentures, flexible materials, chewing pressure.

© **Konovalov S.V.**

Vinnytsia National M.I. Pirogov Memorial Medical University, Normal Physiology Department, Pirogov Street 56, Vinnytsia, Ukraine, 20018 e-mail [ksv55-5513@rambler.ru](mailto:ksv55-5513@rambler.ru)

## **CLINICAL AND MORPHOLOGICAL CHANGES IN ALCOHOLIC CARDIOMYOPATHY (RETROSPECTIVE ANALYSIS)**

**Introduction.** Alcoholic cardiomyopathy (ACMP) is the heart disease that develops in alcohol abuse and due to its toxic effects on the myocardium. This term was first proposed by W. Bridgen in 1957, but alcoholic heart disease was first described in the 19<sup>th</sup> century in Munich citizens who drank 430 liters of beer a year. Due to continuous alcohol consumption for 8-10 years ACMP mortality reaches 40-80% (V. Kreuter), mostly in people aged 40-50 (R. Minkin).

The purpose of the work was to investigate the diagnostic value of clinical and morphological features of ACMP and their use to establish the degree of expert opinion reliability of the cause of death.

**Materials and methods.** The research materials were the archives of Vinnytsia Regional Pathologic Office and Vinnytsia Regional Pirogov Clinical Hospital for 2000-2012. During the research there were examined 110 medical records in patients of the Cardiological Department, pathologic study of dead males aged 35 to 64 whose cause of death was ACMP. The main clinical manifestations of the disease (complaints, medical history, physical examination data), the results of instrumental (ECG, Echo-cardiography, x-ray) and laboratory studies and morphological signs of ACMP were analyzed. To analyze the data, the methods of mathematic statistics were used: quantitative analysis and sequential recognition method, the Bayes method among them. The frequency of the symptoms of ACMP was determined, which was the base of the diagnostic value of the signs in the coefficients form.

**Results.** We concluded that the main symptoms of the disease are: heart failure, cardiomegaly, gallop rhythm, cardiac rhythm disorder and the thromboembolic complications.

The frequency of morphological symptoms of ACMP are not common. The following signs are the most common: the heart cavities enlargement, sclerosis of the soft brain tissues, the brain swelling, dark and thin blood were observed in 93.6% of cases.

**Conclusion.** 1. The death from ACMP often occurred in people whose alcohol consumption was high (80%).

2. It was found that the death from ACMP occurred in more than half of cases because of the lack of ethanol in blood and urine (53.6%). In patients who had adequate ethanol in blood and the urine the death occurred from mild alcoholic

intoxication (0,5-1,4 ‰), that is 50%, from moderate intoxication it was rare (1,2-2,4%, that is 28.2% and from a very severe intoxication (2,5-3,5 ‰) that is 17.3%. Only two cases showed a little effect of alcohol on the organism (0,4 ‰).

3. There was determined the frequency of occurrence and statistic value of macro- and micromorphological signs of cardiological myopathy which are distinguished by unevenness and let judger of the diagnostic value of the signs. Some features have a high frequency of occurrence, for example, of morphological signs these are: dilatation of the heart cavity, sclerosis of soft medullar membranes, edema of the brain, dark and thin blood which occurred in 94%, and their statistic value made 3% , there were also signs which had a lesser frequency of occurrence – anemia of the splin , edematicity of the eyelids, minor hemorrhages in the adjacent membranes of the eye, parietal thrombi in the heart cavities, involuntary urination and defecation. Their occurrence frequency is within the range of 4 to 29%, while the statistic value – 0.1 - 0.9%.

4. There were also studied micromorphological signs, their occurrence frequency is uneven as well. The largest occurrence frequency of micromorphological signs made 100%, while the least was 0.1%, thus the statistic value was also uneven and made 3.2% to 0.3%.

5. A set of the statistic data of diagnostic symptoms determines the degree of reliability of the expert opinion on the cause of death from ACMP. Thus the way of improvement of the diagnostics of the death causes from ACMP by means of mathematical assessment, the summarizing of diagnostic signs, which provides the accuracy and quality of the pathological and forensic examinations is proposed.

In further studies it is planned to determine the diagnostic value of clinical signs as coefficients in ACMP.

**Key words:** alcohol, heart, alcoholic cardiomyopathy.

© **Korobko O.A.**

Vinnitsa National Pirogov Memorial Medical University, Department of Internal Medicine No. 2, (Pirogov Street, 56, Vinnitsa, Ukraine, 21018)

## **GENDER-AGE DIFFERENCES AND CORRELATION RELATIONSHIP BETWEEN THE LIFE QUALITY INDICATORS AND RESPIRATORY FUNCTION IN THE PATIENTS WITH BRONCHIAL ASTHMA**

**Introduction.** The analysis of a sex-age structure and life quality indicators of women and men of different age groups is used for different purposes in medical practice: for determination of effectiveness of a drug or treatment method in clinical researches, for prediction of a disease course, analysis of the ratio of expenses and effectiveness of medical aid in pharomeconomics, in medical audit, for determination of psychological problems and supervision over patients in the general practice system.

*The research objective* is to study age and sex differences and correlation relationship between the life quality indicators and respiratory function in the patients with bronchial asthma with different treatment regimen.

**Materials and methods.** 118 patients were examined for persistent bronchial asthma of medium severity. The average age of the patients from the main group made up  $(45,9 \pm 1,8)$  years, of the control group –  $(48,3 \pm 1,7)$  years. For determination of the quality life of the patients with bronchial asthma the Ukrainian version of the general survey Medical Outcome Study Short Form-36 (MOS SF-36) was used. The respiratory function was estimated using a computer spirograph "Pulmovent - 1" (produced in Ukraine).

With the help of Spearman's correlation coefficient (rs) the influence of the respiratory function indicator - forced expiratory volume during the first second on the life quality criteria of the respondents was studied.

**Results.** The results of the received data show that the total number of the examined was 47 (39,8 %) men and 71 (60,2 %) women. The total number of the patients aged 18-44 was 52 (44,1 %), aged 45 – 59 years – 36 (30,5 %) , patients of 60 – 74 years – 30 persons (25,4 %). Among them there were 44,7 % of men aged 18-44, 17% aged 45-59 and 38,35% aged 60-74. There were 43,7 % of women aged 18-44, 39,4% aged 45-59 and 16,9% aged 60-74.

The received data show that among the examined patients with bronchial asthma in most cases there were people aged 18-44 and the number of women prevailed.

Bronchial asthma decreased the patients' life quality indicators that did not correlate with the respiratory function indicators in all the examined patients (feedback or insignificant direct correlation relationship was determined).

**Conclusions.** Thus, study of the sex and age as bronchial asthma risk factors, life quality indicators and correlation relationship of the criteria of physical, psychic and general status with clinical parameters can help a doctor to understand the disease influence on a patient's life more deeply, determine his/her individual reaction to the disease.

**Key words:** asthma, quality of life, respiratory function.

© Mantak G.I.

Department of Pediatrics № 2 Vinnitsa National Medical University named after NI Pirogov (Pirogov Street, 56, Vinnitsa, 21018, Ukraine)

## **SOME ASPECTS OF PHYSICAL DEVELOPMENT OF CHILDREN, BORN TO PARENTS WHO WERE EXPOSED TO IONIZING RADIATION IN THE ANTENATAL PERIOD**

**Introduction.** The rates of morbidity for both children and adolescents have significantly increased in recent years, negative trends in their health is associated with deterioration of physical development. The processes of growth and

development are determined by genetic and phenotypic factors. Children and adolescents are particularly sensitive to influence of external factors. In some literature, there are reports on how low doses of ionizing radiation affect the level of physical development of children. The authors point to the disturbance in harmonious development of children affected by the Chernobyl nuclear disaster, including those which occur in due time. However, the effect of ionizing radiation on the physical development of children born to parents exposed to ionizing radiation in the antenatal period of development has not been studied.

*Objective:* to examine the state of the physical development of children born to parents exposed to ionizing radiation in the antenatal period.

**Materials and Methods.** For Observation, 150 children aged 6 to 10 years born to parents who are exposed to ionizing radiation in the antenatal period of development and constantly living in contaminated areas were taken. We have conducted a comprehensive survey of children for the study of physical development. The program survey included instrumental examinations as needed. Data collection was carried out on children and retrospectively from medical records. Comparison group consisted of healthy children of similar ages, born of parents who have not undergone ionizing radiation during their ante-and postnatal development. Comprehensive assessment of adolescent physical development was carried out with a table with scores based on height, weight, head and chest circumference.

**Results.** According to the results of our study, when comparing the average age-wise parameters of height in children in surveyed groups, we found no significant differences. Analyzing the individual parameters of physical development of children by percentile tables, we found that delayed growth occurred in  $5,40 \pm 1,95\%$  of surveyed primary group (girls  $2,80 \pm 1,04\%$  and  $2,60 \pm$  boys in  $0,97\%$ ), which is not very different from the index of delayed growth in children of the compared group which was  $5,13 \pm 2,21\%$  (girls  $2,51 \pm 1,11\%$ , in boys  $2,62 \pm 1,16\%$ ) (  $p < 0,05$  comparing surveyed and control group). However, high growth in children of surveyed group occurred in  $8,53 \pm 0,79\%$  girls and  $9,10 \pm 0,82\%$  boys, while in the compared group of children - at  $10,63 \pm 1,90\%$  of girls and  $10,81 \pm 1,92\%$  boys. Significant difference in body weight is not observed ( $p > 0,05$ ). Note the group of children who have growth retardation coincided with a decrease in body weight ( $5,31 \pm 1,38\%$  among children of the main group and  $3,20 \pm 1,18\%$  for the compared group of children). We evaluated the harmony of the physical development of children. We found that the number of harmoniously developed children in surveyed group (test group) is  $69,10 \pm 2,86\%$  while that of the compared group (control group) is  $73,50 \pm 2,97\%$ .

**Conclusions.** 1. Physical development of children born to parents exposed to ionizing radiation in the antenatal period generally is no different from that of children born to parents who have not undergone ionizing radiation during their ante-and postnatal development. The same result was found which assessing the harmony of physical development of the examined groups of children.

There is good prospective for further research to study the incidence of development of diseases of the musculoskeletal system in children born to parents exposed to ionizing radiation in the antenatal period.

**Key words:** children, physical development, ionizing radiation.

© Pypa L.V., Svistilnik T.V.

Vinnitsa national medical university named by N.I.Pirogova, department of pediatrics of faculty advanced studies (str. Pirogova 56, Vinnitsa, Ukraine, 21018)

## **RISK OF OCCURRENCE OF COMPLICATIONS FROM PARTY CNS AT CHILDREN WITH THE ACUTE MENINGITIS DEPENDING ON LEVEL IN WHEY OF BLOOD OF EXCITOTOXIC AMINO ACIDS AND AUTOANTIBODIES TO SUBUNIT NMDA-RECEPTORS NR2A**

**Introduction.** Considerable role in development of damages neurons owing to an ischemia the role plays superfluous allocation raising neurotransmitters amino acids, such as glutamate (Glu) and aspartate (Asp) which activating subtypes glutamate receptors N-Metil-D-Aspartat (NMDA) lead to massive occurrence inside neurons calcium ions which activates proteases which action are directed on damages of cellular structures that forms a phenomenon basis excitotoxicity. The destroyed NMDA-receptors, cause reaction of immune system with formation of NR2-antibodies, titre which are offered for using as markers of ischemic damage of the central nervous system (CNS).

Concentration of Glu in liquor accurately correlates with concentration of Glu in blood at acute meningitis (AM) at the expense of hit of brain Glu in blood through a gradient of concentration and damaged blood-brain barrier.

Considering above presented data, an objective of this research began to define prognostic values of concentration of exciting amino acids in whey of blood and autoantibodies to subunit NMDA-receptors on risk of occurrence of complications from party CNS at children about the AM.

**Materials and methods.** Research of samples of blood of 73 children about the AM (40 with serous and 33 with purulent) age from 1 month till 18 years which were treated in Khmelnytsky infectious hospital with 2010 till 2012 is conducted. Definition in blood whey excitotoxicity amino acids of Glu and Asp was spent by a method ion exchange liquid- column chromatography at institute of biochemistry by name O.V.Paladin NAN Ukraine (Kiev) at 73 patients and at 30 healthy children. Quantitative definition of antibodies to NR2- subunit a NMDA-receptor in blood whey was defined immunoferment a method (ELISA) with use of test systems Gold Dot NR2 Antibody Test "Glutamat Kit" by firms BCM Diagnostics (USA) at 40 patients and at 10 healthy children. In laboratory of Vinnitsa national medical university named by N.I.Pirogova. Samples of blood received in 1 days after hospitalization. Statistical processing of results was made by means of criterion of Student's, definition of absolute risk (AR), by odds ratio (OR) and constructions of 95 % of a confidential interval (CI) for a difference of averages AR end OR.

**Results.** Complications from party CNS were observed at 39 patients about the AM: an asteno-vegetative syndrome - 69,2%, a convulsive syndrome - 20,5%, a hydrocephaly - 12,8%, a brain edema - 12,8%, paralysis - 3,7%, ventrikulitis - 3,7%. Authentic increase of Glu in whey of blood of children 3 the AM (n=73) in the first days of disease, in comparison with healthy (n=30) is defined:  $154,1 \pm 99,4$  and  $45,4 \pm 16,3$  mkmol/l, ( $p < 0,001$ ) (95 % CI, 72,-145,1 mkmol/l), and also Asp:  $51,3 \pm 21,6$  and  $9,2 \pm 3,9$  mkmol/l, ( $p < 0,001$ ) (95 % CI, 34,2 - 49,9 mkmol/l) accordingly. Levels of Glu and Asp authentically were big at patients with complications from party CNS (n=39) in comparison without them (n=34):  $190,8 \pm 112,2$  against  $112,0 \pm 60,5$  mkmol/l (95 % CI, 35,8 – 121,8 mkmol/l) ( $p < 0,001$ ) for Glu and  $59,8 \pm 22,0$  against  $42,6 \pm 17,7$  mkmol/l (95 % CI 6,9 – 25,7 mkmol/l) ( $p < 0,001$ ) for Asp. Level NR2A antibodies at patients about the AM (n=40) made  $7,42 \pm 5,06$  ng/ml and was big than at healthy children (n=10)  $3,22 \pm 1,12$  ng/ml, where ( $p < 0,05$ ) (95 % CI, 0,94 - 7,46 ng/ml). Level antibodies was big at patients with complications (n=25) in comparison without them (n=15):  $8,94 \pm 5,73$  against  $4,88 \pm 1,92$  ng/ml (95 % CI, 0,95 - 7,16 ng/ml) ( $p < 0,05$ ).

The risk of occurrence of complications from party CNS authentically increases at achievement of concentration of Glu in blood  $\geq 75,0$  mkmol/l or in 1,6 times in comparison with healthy children where OR makes  $>1$  (95 % CI, 1,14 – 84,79). AR thus makes  $58,4 \pm 4,9$  % (95 % CI, 48,8 – 68,0 %) in the exhibited group against  $14,2 \pm 9$  % (95 % CI, -3,4 - 31,8 %) in not exhibited. The risk of occurrence of complications from party CNS authentically increases at achievement of concentration of Asp in blood  $\geq 40,0$  mkmol/l or in 4,3 times in comparison with healthy children where OR makes  $>1$  (95 % CI, 58,1- 76,5). AR thus makes  $67,3 \pm 4,7$  % (95 % CI, 58,1 - 76,5 %) in the exhibited group against  $29,6 \pm 4,5$  % (95 % CI, 20,8 - 38,4 %) in not exhibited. The risk of occurrence of complications from party CNS authentically increases at achievement of concentration NR2A antibodies in blood  $\geq 5,00$  ng/ml or in 1,5 times in comparison with healthy children where OR makes 10,28 (95 % CI, 5,1 – 64,9). AR thus makes  $80,0 \pm 4,0$  % (95 % CI, 72,2 - 87,2 %) in the exhibited group against  $45,0 \pm 4,9$  % (95 % CI, 35,4 – 54,6 %) in not exhibited.

**Conclusion.** 1. The risk of development of complications from party CNS statistically significantly increases at concentration of Glu in blood  $\geq 75,0$  mkmol/l, Asp  $\geq 40,0$  mkmol/l and testifies to presence of the minimum values for these substances at which complications can be formed.

2. The risk of development of complications from party CNS statistically significantly increases at concentration NR2A antibodies in blood  $\geq 5,00$  ng/ml and testifies to presence of degree of a cerebral ischemia at which possibility of occurrence of complications in CNS considerably increases.

3. Concentration of Glu, Asp and NR2A antibodies can be used for forecasting of development of complications from party CNS that will give the chance to optimize treatment.

**Key words:** a meningitis, children, amino acids, complications.

© Yuzvyshyna O.V.

Vinnitsa Pirogov National Medical University. (Pirogov Str., 56, Vinnitsa, 21018, Ukraine)

## **DYNAMICS OF THE METABOLIC SYNDROME IN PATIENTS WITH ESSENTIAL HYPERTENSION AND HEART VALVE CALCIFICATION DUE TO ATORVASTATIN TREATMENT**

*Aim:* Calcification of the heart valves is often associated with hypertension and dyslipidemia, which may accelerate fibrotic processes in the valves.

**Objective:** To study the effect of different variants of lipid-lowering therapy on blood lipid and uric acid (IC) in patients with essential hypertension (EH) and the presence of heart valves calcification (HVC).

**Methods:** Under the supervision were 245 patients with EH II-III and HVC, the average age ( $71,3 \pm 0,5$ ) years, during 3 years of monitoring took offered them the option of basic antihypertensive and lipid-lowering therapy. Variants of lipid-lowering therapy: 1-variant (atorvastatin (Atorvaktor) 10 mg/d without dose adjustment), 2-nd variant (atorvastatin (Atorvaktor) 10 mg/d+omega-3 polyunsaturated fatty acids 1 g/d without dose adjustment), 3-and option (starting dose of atorvastatin (Atorvaktor) 10 mg/d with dose adjustment according to the level of LDL, the target LDL level  $<2.0$  mmol/L), 4-th option (atorvastatin (Atorvaktor) 40 mg/d without dose adjustment in subsequent ). At the beginning of the study and every year of observation for all patients performed a comprehensive survey. Lipid profile (total cholesterol (TH), low density lipoprotein cholesterol (LDL), high density lipoprotein cholesterol (HDL), triglycerides (TG)), uric acid (UA) content in the blood was determined by biochemical analyzer Roche (Switzerland) with a set of reagents firms Sobas. Results expressed in mmol/L.

**Results:** Found that in patients with essential hypertension and HVC after 3 years of observation significantly better reduction in total cholesterol were patients in groups 3-th (-50.7%,  $p < 0.0001$ ) and 4-th (-56.5%,  $p < 0.0001$ ) options. Also the level of TG had similar significant differences. Patients in groups of 3-rd and 4-th treatment options for dynamic reduction of TG after 3 years of follow-up was higher values: group 3 (-8.6%,  $p=0.009$ ), group 4 (-10.3%,  $p=0.006$ ). This pattern persisted through 3 years of observation in the analysis of LDL cholesterol. The lowest average values of LDL were observed in patients with 4 embodiment lipid-lowering therapy - 1,96 (1,52; 2,17) mmol/l. Although the level of HDL cholesterol were significant difference in each group each year, but the highest increase in 3 years was observed in the group with 4-m option of treatment (28.8%,  $p < 0.0001$ ). At the 3-rd option after 3 years the level of UA patients was significantly lower at 9.4% ( $p=0.020$ ) compared with baseline, and at 4-th version - by 10.3% ( $p=0.012$ ), respectively, and was the lowest average value of 0,29 (0,22; 0,34) mmol/l.

**Conclusions:** Levels of total cholesterol, triglycerides, LDL cholesterol was significantly lower in patients with lipid-lowering therapy following options: starting dose 10 mg/day Atorvaktor with correction dose by level of LDL Atorvaktor receiving



a dose of 40 mg/day without dose adjustment. The highest increase in HDL cholesterol level after 3 years was observed in the group with 4-m treatment option (the reception Atorvakor dose of 40 mg/day). Significant decrease of the concentration of uric acid in the blood was observed after 3 years of observation in the following patient groups: the starting dose of 10 mg/day Atorvakor with correction dose by level of LDL Atorvakor receiving a dose of 40 mg/day without dose adjustment.

**Key words:** hypertension, heart valve calcification, lipid-lowering therapy, lipid profile, uric acid, atorvastatin.

© **Boiko A.A.**

Vinnitsa National Pirogov Memorial Medical University, Course of Addiction Medicine, Psychiatry, Postgraduate Education Division (56 Pirogov str., Vinnitsa, Ukraine, 21018, e – mail: admission@vsmu.vi admission@ vsmu.vi)

## **ASSOCIATED FORMS OF WOMEN'S ALCOHOLISM**

**Introduction.** There is a number of disputed issues related to clinical peculiarities of women's alcohol dependence, particularly to associated pathology in the clinical course of alcohol dependence. In view of the above the objective of our research was to study the regularities of development and outcomes of the associated forms of women's alcoholism depending on the comorbid psychiatric pathology and peculiarities of the disease clinical dynamics.

**Materials and methods.** The research involved 180 women suffering from alcoholism that underwent repeated alcoholism treatment. The main group included 130 women with the second stage of alcohol dependence accompanied by arterial hypertension, consequences of a craniocerebral trauma, comorbid psychiatric pathology. The average age of the patients at the time of the examination was  $41,8 \pm 6,8$  years. The first subgroup included 50 women suffering from alcohol dependence with hypertonic brain affection; their hypertonic disease had been diagnosed on the average 5 years earlier than alcohol dependence. The second group included 45 women suffering from alcohol dependence with traumatic brain affection, earlier craniocerebral traumas of different severity had also preceded formation of alcohol dependence (5 years earlier on the average). The third group consisted of 35 women that had suffered from diagnosed psychiatric disorder before alcohol dependence (5 years earlier on the average), because of which they applied to clinic. The comparison group was represented by 60 examined women who suffered from the second stage of alcohol dependence and had not experienced arterial hypertension, signs of craniocerebral traumas, verified affective pathology earlier. Statistical standardization of the patients of the main group to the comparison group was performed according to the sex, age and educational level.

The following methods were used in the research: clinical-psychopathologic, clinical-dynamic, statistical.

**Results.** The clinical-dynamic analysis of formation of the main dependence syndromes accompanying associated forms of women's alcoholism revealed an accelerated tempo of their establishment: an average duration of the period from clinical manifestation of pathological alcohol addiction until development of the alcohol withdrawal syndrome in case of comorbid brain injury of the traumatic genesis made up  $6,7\pm 3,2$  years; in case of comorbid brain injury of the vascular genesis -  $8,3\pm 2,9$  years; in case of comorbid psychic pathology (depressive episode of mild and medium severity, reaction to a severe stress and desadaptation, emotionally unstable personality disorder, hysterical personality disorder) -  $9,1\pm 3,1$  years. The clinical picture of the main alcohol dependence syndromes in women with associated forms of alcoholism was characterized by the following peculiarities: a high frequency of occurrence of a changed drunkenness picture was revealed in formation of alcohol dependence represented by shortened euphoria periods, irritability, emotional lability, depressive and hysterical episodes; alcohol withdrawal syndrome was distinguished by a prolonged clinical course.

**Conclusion.** The women with associated forms of alcoholism were born in the families suffering from alcoholism. A clinical peculiarity of associated forms of women's alcoholism is reduction of the duration of all its formation stages.

Clinico-dynamic analysis of formation of the main syndromes depending of associated forms of alcoholism in women has revealed that the average duration of the clinical manifestations of craving for alcohol before the development of withdrawal symptoms when comorbid brain injury traumatic genesis was  $6,7\pm 3,2$  years; Comorbidity with brain damage of vascular origin -  $8,3\pm 2,9$  years; with comorbid mental disorders (depressive episode mild or moderate reaction to severe stress and adjustment disorders, emotionally unstable personality disorder, histrionic personality disorder) -  $9,1\pm 3,1$  years.

In the formation of alcohol dependence often changes the picture of intoxication - shorter periods of euphoria.

**Key words:** women, alcoholism, brain trauma, hypertension, co-morbid psychological disorder.

## ***METHODICAL ARTICLE***

© Guryev S., Tanasienko P.

Ukrainian Emergency and Disaster Medicine Center, Kyiv, Ukraine

## THE SELECTION OF METHOD OSTEOSYNTHESIS AS PREVENTION OF INFECTIOUS COMPLICATIONS PATIENTS WITH SKELETAL COMPONENT POLYTRAUMA

**Introduction:** In the last decade the development of technological society has led to an increase in the number of injuries and poisonings worldwide. Transport, construction, local wars and conflicts - that is not an exhaustive list of the factors that influence on the dissemination of traumatism. Victims with polytrauma are the most severe trauma injuries. Quantity of a road accident, natural disasters and man-made disasters reaches 50-79%.

*The aim* of our work is to compare the occurrence of infectious complications in casualties with skeletal component polytrauma that was operated by different methods of internal osteosynthesis.

**Materials and Methods.** During our study we have analyzed the treatment of 115 victims of the skeletal component of trauma which were in one of the city hospitals in Kyiv in the period of 2008-2010. There were 79 male (68.69%) and 36 female (31.31%). The criteria for inclusion in this study were the presence of the polytrauma with the assessment of severity of  $\geq 20$  points on a scale Lyndzau in modification of G.O. Mozhaeva and I.O. Malysh. The skeletal component included the presence of closed and open injuireis (1,2,3<sup>th</sup> A-type's, Hastylo-Andersen classification).

**Results.** For general objective assessment, we have recorded all infectious complications that occurred in casualties in the postoperative period. Those infectious complications have ranged from the superficial maceration to the posttraumatic osteomyelitis. In the control group, infectious complications were found in 31 (40.26%) injured. In the main group were stated 8 victims with different infectious complications (21.08%). Summarizing the given facts, it can be specified that only the use of the locking intramedullary rods in the second period of surgical treatment of patients with polytrauma reduces the likelihood of complications nearly doubled. It was a significant trend of more easily course of the identified infectious complications with internal osteometalsynthesis blocking intramedular rod. Moreover, complications haven't evolved to the extreme cases.

**Conclusions:** 1. The major health problem that currently hasn't solved enough is the infectious complications of polytrauma;

2. It is much more perspective to use the blocking intramedullary osteometalsynthesis. It halves the likelihood of infectious complications in casualties with skeletal component of polytrauma;

3. It was discovered a significant trend of more easily course of infectious complications patients with polytrauma due to use of blocking intramedullary osteosynthesis.

**Key words:** polytrauma, injuries, osteometalosyntes.

Vinnitsa National Pirogov Memorial Medical University, Biological and General Chemistry Department (Pirogov st., 56, Vinnytsya, Ukraine, 21018)

## APPLICATION OF PROTEONECTIC PROPERTIES OF SILIKS FOR TREATMENT OF ACNE VULGARIS

**Introduction.** On the modern stage is traced tendency to growth of level of morbidity on acne vulgaris which specifies on the important medical and medico-social value of problem [Klimenko, Stepanenko, 2008].

Researchers considers acne vulgaris at the most widespread dermatosis, which arises up at the beginning of pentatonic period, acquires development in youth age and slowly regresses in an early grown man period, that is related to the physiological age-old features [Shupen'ko, Stepanenko, 2009].

*General aim:* theoretical explanation of application of proteonectic properties of silics for treatment of acne vulgaris.

**Materials and methods.** Ordinary acne – it is general inflammatory violation of functioning greasy hair follicles [Korolenko, 2008]. At the skin rash that easy form a skin practically is not added inflammations.

To the easy stage acne take such types of skin disease: micro comedones, opened comedone, closed comedones, «lipomas», valid for one occasion of skin disease. Acne vulgaris illness of middle and heavy forms finds out the strong destructive operating on a skin. To them take abscesses or red disease.

As a result of analysis of methods of treatment of skin diseases in the past the most important are selected among them: 1800th – is the use of sulphur; 1920th – is the use of benzoilperoxide; 1930th – is the use of purgative; 1950th – is the use of antibiotics; 1960th – is the use of tretinoin; 1980th is the use of isotretinoin; 1990th is the use of laser.

**Results.** In Institute of chemistry of surface of NAS of Ukraine together with the Vinnitsa National Medical University Pirogov it is developed and inculcated in medical practice new enterosorbent of wide range action silics (productions of the Kiev pharmaceutical COMPANY «Bio pharm») [Bondar and other, 2004].

Substance is characterized a high chemical cleanness (> 99,8 %) and homogeneity, owns chemical, thermal, radiation and microbiological firmness, high adsorption activity and physiology harmlessness.

The features of chemical structure of surface of silics allows to use it in pharmacy not so much as an auxiliary matter or matrices in the combined medications, but as independent medical preparation of politerapevtic action [Pogorely, 2009].

Proteonectic characteristic of high dispersed silics is an a large value on that reason, that such pathogenic factors have albuminous nature, as microbial enzymes, exo- and endotocsine, most antigens and allergens, toxins of endogenous origin (peptides of middle molecular mass, oligopeptide).

Difference in adsorption of microorganisms makes it possible to explain differences in physical and chemical properties of surface of bacteria, such as a value of isoelectric point, closeness of superficial charge, content of albumen, in a protein glucanoic component [Geraschenko, 2009].

### **Conclusions and perspective of subsequent developments**

1. General description is resulted in classification acne, the methods of his treatment are considered, as general inflammatory violation of functioning greasy hair follicles.

2. In theory grounded application of proteonectic properties of silics for treatment of acne vulgaris.

**Key words:** acne, silics, proteonectic properties.

## ***REVIEW ARTICLES***

© **Kuryk O.H., Gavrilyuk A.O., Stratiychuk A.S.**

Vinnitsya, Khmelnytskyi, Ukraine

### **APUD-SYSTEM BREAST IN NORMAL AND NEOPLASTIC PROCESSES**

The paper presents the data analysis APUD-system of the mammary gland with the use of the literary sources of the Ukrainian and foreign publishers.

Breast cancer today is a leader among cancers in women is the most common cause of death from cancer in the female population [Joshems, Tjalma, 2004; Ando et al., 2006]. Despite the wide range of studies and an even greater number of published papers on the subject, especially some options for breast cancer and their clinical course, treatment and prognosis require further detailed study [Ajisaka et al., 2003; Adegbola et al., 2005].

One of the least studied areas in oncology, including breast cancer, are tumors that contain endocrine cell component or hormonoprodukuyuchi tumors [Bigotti et al., 2004; Kim et al., 2004; Fujimato et al., 2007]. Currently, more defined role of neuroendocrine mediators in the pathogenesis, diagnosis, treatment and prognosis of breast cancer [Upalakalin et al., 2006]. Oncological point of view the most interesting secretion of substances such as serotonin, melatonin, histamine, catecholamines, gastrin, epinephrine and norepinephrine, STH, insulin, glucagon, calcitonin and others [Bergman et al., 2004; Joshems, Tjalma, 2004; Sridhar et al., 2004; Adegbola et al., 2005; Upalakalin et al. 2006].

The successive stages of studying the problem of the morphology of APUD-system in normal of the mammary gland and its impact on the development of various cancer and dyshormonal processes in the mammary gland are described.

**Key words:** APUD-cell system, mammary gland, apudosity, tumor, dyshormonal process.

© **Dronenko V.G.**

Vinnitsia National Pirogov Memorial Medical University, Oncology Department  
(Pirogov str. 46, Vinnitsia, Ukraine)

## **CHARACTERISTIC OF INCIDENCE OF COLON DISORDERS REQUIRING RADICAL SURGERY**

**Introduction.** The aim of the work was to study the prevalence of colon disorders, radical surgical measures being the main method of their treatment.

According to the reports from clinics located in various parts of the world most of operations on the colon are performed for neoplasms. This fact has become especially urgent nowadays because of constant increase of morbidity connected with malignant neoplasms all over the world as a result of growth of population on the planet as well as its aging [Zalit et al, 2006; Aliev, 2007; Chissov, 2008; Humes, 2012]. An impending global epidemic of cancer is being spoken about as of nearly accomplished phenomenon [Arberi, 2001]. Thus by the data and prognoses of International Agency for Research on Cancer (IARC) (Lyons, France) the incidence of new cases of cancer in 2020 will amount to 16 million, that is 6 million cases greater when compared with 2000 [Parkin, 2001].

Nonepithelial neoplasm – sarcoma- takes one of the leading places in the group of malignant tumours. The incidence of these neoplasms has increased in the last decade and makes 2-3% of all colon tumours [Bolyuh et al, 2012].

The main radical method of treatment of blastomatous processes in the colon is surgery as hemicolectomy or colon resection; resectable tumour and absence of peritonitis create necessary prerequisites for primary restorative radical operation with restoration of intestinal continuity by means of applying anastomosis [Matveev et al, 2003, Gantsev et al, 2007; Iinuma et al., 2011].

Surgical procedures on the colon in carcinoids are rare. They are uncommon tumours originating from APUD system cells [Petrov, 1996; Bolyuh et al, 2012].

Increase in the incidence of nononcologic colon disorders are also noted: traumatic and gunshot injuries, diverticulitis, Crohn's disease as well as other inflammatory dystrophic disorders which are not subjected to conservative therapy but require operative measures. Surgical treatment is also done in benign tumours [Zaharash, 2005; Safronov, 2005; Novozhylov et al, 2006; Murray, 1999; Khaikin et al., 2012; Wolff, 2012].

**Conclusions.** 1. The tendency to rapid increase in the incidence of oncologic and non-oncologic colon disorders which require radical surgical treatment is marked nowadays. 2. Present methods of operations on the colon allow to reach full recovery in curable patients.

**Key words:** Blastomatous colon diseases, Crohn's disease, nonspecific ulcerative colitis, hemicolectomy, colon resection.

© Gerych O.H., Grigorenko A.P., Feschenko N.G.

Vinnitsa National Pirogov Medical University, Department of Postgraduate Education, Chair of Obstetrics and Gynecology (St. Hotovitzky 6, Khmelnytsky, 29000, Ukraine)

## FETOPLACENTAL ENZYMES SYSTEMS OF METABOLISM OF XENOBIOTICS

**Introduction.** In a review is considered enzymes systems of metabolism of xenobiotics in fetoplacental complex. On the short terms of pregnancy a fetus and placenta have small enough sizes, then their functioning substantially does not influence on metabolism of chemicals in the organism of mother, but expression cytochrome P450 enzymes (mainly isoforms of CYP3A), and also UDP glutathione-S-transferase and sulphatases in a placenta and organs of fetus provide them metabolic protecting from harmful influences of external environment. As it is known that almost all medications pass through a placenta barrier, knowledge about the dependency upon the term of pregnancy activating of enzymes 1 and 2 phases of metabolism of xenobiotics will become basis of rational application of medicinal treatment of mother and fetus.

In order to study contemporary literature on fetoplacental enzymatic systems metabolism of xenobiotics an overview of domestic and foreign posts.

In pregnant affects a large number of different chemicals. Their impact is due to treatment of the mother, factors lifestyle habits, such as alcohol, drugs, smoking, occupational and environmental factors, the use of medicines (vitamins, antihypertensive drugs, hormones, etc.). [Babanov, Agarkova, 2010, Myllynen et al., 2005]. They may have an adverse impact on the development and functioning of the placenta, intrauterine fetal development. In order to study contemporary literature on fetoplacental enzymatic systems metabolism of xenobiotics an overview of domestic and foreign posts. Alien mixture disrupt the function of the placenta at many levels, including the synthesis of hormones and enzymes, transport of nutrients, differentiation, division and maturation of cells and, result, lead to destruction and death placenta [Myllynen et al., 2005]. The assertion that the placenta is impermeable barrier to foreign substances today is false. Most chemicals pass the placental barrier. Almost all of xenobiotics that enter the mother's body during pregnancy enter the bloodstream of the fetus by passive transport, passive diffusion, pinocytosis, phagocytosis, some fall through active transportation of - with transport proteins, often localized in microvilli sintsiotrofoblasta or in the endothelium of the capillaries of the villi and provide transport of endogenous substances and xenobiotics across cell membranes. These proteins or transfer of substrates from embryonic tissues in the maternal circulation, or on the contrary contribute to their accumulation in fetal tissue [Serov et al, 1997, Myllynen et al., 2005, 2007; Włoch et al., 2009; Syme et al., 2004 ]. Most xenobiotics transported by transport proteins through the placenta. Also placenta as its structure changes during pregnancy reflected in reduced thickness of the barrier that separates maternal blood from the fetal from 20-30 microns in the first trimester to 2-4 - in the third [Włoch et al., 2009]. The main properties that determine

transplacental transport is the molecular weight, solubility in fats, concentration and protein binding [s Serov et al. 1997, Myllynen and al. 2007]. Almost all soluble xenobiotics pass the placental barrier. For many xenobiotics, including drugs known undesirable effects on the embryo and fetus, including intrauterine death, congenital defects and the formation of functional disorders [Hakkola and al. 1998, Włoch and al. 2009]. Found that most xenobiotics are not necessarily poisonous, but due to enzymatic transformations in the body of the intermediate metabolites become reactive and poisonous properties [Pentyuk et al., 2004, Hakkola and al. 1998]. Placental xenobiotic-metabolizuyuchi detoksykuvaty enzymes can activate or foreign substances, and transporters or increase or eliminate their accumulation or penetration through the placenta [Myllynen and al. 2005]. Placenta to the fetus prevents penetration of foreign substances due to the expression of xenobiotic-metabolizuyuchy enzymes. Understanding the role of the placenta in the delivery and metabolism of drugs - a breakthrough in Toxicology [Prouillac, Lecoeur 2010]. Thus, the placenta and fetus have their own xenobiotic-metabolizuyuchi system that is metabolic basis of fetoplacental system protection from the harmful effects of environmental factors. Thus, the impact of chemicals on the morphofunctional state of the placenta and the fetus due not only to their presence and concentration as well as their metabolites in maternal blood, the degree of penetration through the placental barrier, but metabolic transformations of xenobiotics enzyme systems of the placenta, fetus. As we noted above, the fruit has a very high activity of xenobiotic-metabolizuyuchy enzyme 1-st and 2-nd phase of metabolism that can serve as a kind of protection from the harmful effects of environmental factors and to ensure normal growth and development. As this fruit was subjected of treatment, knowledge of transplacental transport and metabolism of xenobiotics in the placenta and fetal tissues and organs to widen opportunities and optimize pharmacotherapy fetus and predict undesirable influence on the growth and development of some medicines.

**Conclusion:** Fruit and placenta have their own enzymatic systems 1 and phase 2 metabolism of xenobiotics. 2. Expression, depending on gestational age, certain isoforms of cytochrome P450 in the placenta (CYP1A2 SUR3A4, 3A5) in embryonic and fetal liver (CYP1A1, CYP1B1, CYP2C8, CYP2D6, CYP2E1, CYP3A4, CYP3A5 and CYP3A7), and UDP-hlyukuronozyltransferazy and sulfate in tissues placenta may serve as a metabolic basis for survival and normal development of the fertilized egg in the adverse effects of environmental factors.

**Key words:** fetus, placenta, xenobiotics, cytochrome P450.

© Korol T.M.

Vinnitsa National Pirogov Memorial Medical University (Pirogov Street 56, Vinnitsa, Ukraine, 21018)



## ULTRASTRUCTURAL CHANGES OF PLACENTA AND THE ROLE OF KASHENKO-HOFBAUER CELLS IN ANTENATAL INFECTING WITH DEVELOPMENT OF FETOPLACENTAL INSUFFICIENCY

**Introduction.** In the study of placental insufficiency arising from antenatal infection, a special place occupy protective mechanisms that can compensate for the action of pathogenic factors. Using literature the role of placental macrophages and major ultrastructural changes of the placenta at FPI are analyzed.

Fetoplacental insufficiency - one of the basic problems of obstetrics, neonatology and pathology diseases ante-and perinatal period, as the functional inability of the body leads to the threat of termination or miscarriage, growth retardation and fetal development or fetal death.

In the study of placental insufficiency are particularly important protective mechanisms (cellular and humoral) that can compensate for the action of pathogenic factors. Among cellular agents particular importance have placental macrophages, or cells Kashchenko-Hofbauera (KKH), but in the literature are not enough data about them.

*The aim* of our study was to trace according to literature data ultrastructural changes of the placenta at antenatal infection that led to the development of fetoplacental insufficiency and role of Kashchenko-Hofbauer cells in compensatory-adaptive processes in the "mother-placenta-fetus."

First large oval cells in the stroma of placental villus were observed in 1885 and our countryman M.F. Kashchenko called them "wandering cells". In 1905 J. Hofbauer published a detailed description of these cells in human placental villus in the normal and later they were called "Hofbauera cells." In Soviet literature the term "Kashchenko-Hofbauera" cells is used. The origin of these cells and their functions in the literature is still a subject of debate. It was believed that they descended from decidual tissue of the mother, or with syntytiotrofoblastu villus, which indicated a proliferative growth because KKH always detected in vesicular skidding. An important factor for determining the origin of these cells was the identification of sex chromatin, which indicated embryonic or placental origin of KKH.

**Conclusions:** 1. Thus the antenatal infection placental dysfunction is characterized by hypoplasia of the placenta due to immaturity of chorionic villus and sclerotic processes of reduction of gaps capillary ultrastructural pathology syntytiotrofoblasta considerable expansion and consolidation of placental barrier.

2. KKH role in this pathology is still controversial and requires study in the future. A comprehensive electron-microscopic and immunohistochemical study of KKH are necessary and their importance in the morphogenesis of fetoplacental insufficiency at antenatal infection.

3. The presence of severe violations diffusion capacity of the placenta dictates the need for further development of preventive and therapeutic activities aimed at correcting these changes.

**Key words:** chronic placental insufficiency (FPI), cells Kashchenko-Hofbauera (KKH), electron-microscopic study, ultrastructural changes, placenta, chorionic villus.

© Mnikhovich M.V., Tsiperovich K., Yakhonson M., Giterman Ts., Gavriilyuk A.A., Fomina L.V., Guminskiy Yu.I., Vernigorodskiy S.V., Ternov M.M., Miglyas V.G.

Moskva (Russia), Vinnitsya, Uzhgorod (Ukraine)

## **INTERCELLULAR INTERACTIONS AT CELL INVASION: MORPHOLOGICAL AND MOLECULE-BIOLOGICAL PECULIARITIES**

One of the main problems of modern oncology is the study of the most dangerous property of malignant tumors their ability to invasion and metastasis. Destruction of stable cell adhesion and getting ability of cell to migrate plays a significant role in invasive potential of transformed epitheliocytes.

Main factors, influencing on invasive abilities of cancerous cells, are the proteins of intercellular adhesion, extracellular matrix enzymes, components of plasminogen activating system, components of basal membrane, enzymes-suppressors of tumor growth and metastasis.

Invasive growth is a complex morphogenetic program which integrates at first sight such independent processes as migration, natural selection, degradation of extracellular matrix and induction of cell polarity.

Many publications, devoted to a problem of invasive and metastatic ability of tumor cells, confirm that the phenomenon of invasion and metastasis of tumor cells is a consequence of acquirement a number of phenotypic characteristics: disregulation of adhesive interactions of tumor cells with each other and with intact cells of microenvironment and extracellular matrix; production of proteolytic enzymes, disturbing extracellular matrix; acquiring by a cell a locomotor phenotypr, including changes in morphology and cytoskeleton; angiogenesis induction, producing additional ways of primary tumor cells evacuation.

Lot of accumulated information argument, that genes, controlling cellular cycle in norm, are changed in tumors. Besides the well-known tumor suppressor genes p53 and Rb (retinoblastoma), there are CDK (CDK4), gene of cyclen (CCND1) and CDI gene (p16INK4A), seducing activity of two kinases — CDK4 and CDK6.

Mechanisms, determining the ability of tumor cells for local penetration into surrounding healthy tissues, including the microcirculatory system, lymphogenic and hematogenic dissemination, detention in certain parts of microcirculatory bed with the following penetration of the vessels wall and formation of secondary loci of tumor growth, - are poorly understood nowadays.

An ability to invasion of cells in primary tumor is expressed not equally. Cell proliferation is a parcel part of invasive growth and is accompanied by disturbance of intercellular contacts.

Superincumbent cells are attached to each other of to components of microenvironment with the help of molecule of intercellular adhesion.

Tumor cells in invasive growth enter the contacts between cells and structures of extracellular matrix of surrounding normal tissues. Penetrated into the circulation system, tumor cells come into contacts with endothelium, and then with subendothelial matrix structures, exercising extravasation and formation of metastasis.

Specificity of contacts of tumor cells with host cells and extracellular matrix is realized by a wide spectrum of adhesion molecule, localized on the surface both tumor and norm cells, endothelial cells in particular. In mammary gland, urinary bladder, pulmonary and body uterus cancers mutations of genes kadherins and kateins take place, leading to weakening of intercellular contacts. Furthermore, modification of structure and insufficiency of kadherins and kateins increase the ability of tumor for metastasis.

Tumor invasion and metastasis are multiphase and closely related to each other processes. Invasive and metastatic ability of tumor cells is a consequence of acquisition of a number of phenotypic characteristics:

- disregulation of adhesive interactions of tumor cells with each other, with norm cells of microenvironment and with extracellular matrix;
- production of proteolytic enzymes, that destroy extracellular matrix;
- acquisition of cell locomotor phenotype, including change of morphology and cytoskeleton;
- angiogenesis induction, providing additional ways of primary tumor cells evacuation.

Obviously, that these different phenotypic signs are determined by an expression of different molecule, encoded by the genes of two conditional groups: activator and supressors of invasion and/or metastasis.

Tumor cells are able to aggregate in groups in process of circulation. This process is facilitated due to homophilic and heterophilic adhesion. Forming of platelet-tumor units increase ability of malignant tumor cells for survival and further implantation in surrounding tissues. Then the retention of tumorous embolus takes place in the point of it attachment to endothelium and penetration of its cells outside the basal membrane towards extravasal tissues. Molecule of cell adhesion (integrins and selectins) and proteolytic enzymes take place in these processes.

**Conclusions.** Summarized the data, we came to the following conclusions:

1. Invasive properties of tumorous cells and their ability to form metastasis determine prognosis of new growth.
2. The properties, mentioned above, cells acquire during a number of consequent mutations, regarding fundamental molecular-biological mechanisms – metabolism, exchange of information, growth, proliferation and destruction.
3. Migration the tumorous cells outside the primary foci, their ability to invasion, is a main stage of tumorous growth. Forming of metastasis takes place as a result of consequent independent events – neoangiogenesis, invasion, embolization of vessels, migration, adhesion to the wall of blood vessels, forming of own microenvironment and proliferation of cells in target organs.
4. At every stage of carcinogenesis different growth regulators play an important role. The main role in neoplastic cell transformation and malignant growth belongs to

adhesive molecule, ECM components, metalloproteinase matrix and their inhibitors, factors, stimulating angiogenesis in tumors – trombospondins, endothelial growth factor (VEGF) and some others, inactivation of regulatory proteins, determining apoptosis.

**Key words:** invasion, metastasis, cell adhesion, extracellular matrix, tumor, migration.

© **Semenenko S.I.**

Vinnitsya, Ukraine

## **VERTIGO SYNDROME: CLASSIFICATION, DIAGNOSTICS, AND ADVANCED THERAPEUTIC STRATEGY**

This article contains the information about one of the most common complaints among the patients of all ages - vertigo, causes, classification, diagnostic algorithms and modern methods of pathogenetic treatment.

Dizziness is a symptom of various diseases that adversely affect quality of life. This is one of the most common complaints of patients physical and neurological. Dizziness may be a symptom of a wide variety of physical and mental diseases, diseases of the ear, eye and cardiovascular system [Boiten et al., 2003]. Dizziness is a symptom of always and never the disease. As well as pain, fear, depressed mood, vertigo refers to the subjective complaints of the patient. Vertigo - a violation of the body's orientation in space - the patient feels the movement of the body in space (subjective vertigo) or the movement of objects around their bodies (objective vertigo), usually with a loss of balance [Amelin, 2006]. Equilibrium - a person's ability to retain a stable upright position at rest, walking and performing other movements. For this function meets one of the oldest senses - the peripheral vestibular system and central vestibular nerve pathways. Mechanism for maintaining equilibrium depends not only on the vestibular, but also on the visual, proprioceptive and surface-sensory information.

Cause of vertigo is an imbalance of sensory information from afferent systems that provide spatial orientation - the vestibular, visual and proprioceptive. Are also important disorders of the central data processing unit and efferent motor act.

*Objective:* To analyze the main causes of vertigo, clinical manifestations, diagnostic techniques and modern methods of treatment of vestibular disorders.

Syncope and presyncope. These terms represent the state in the form of nausea feeling of general weakness, nausea, discomfort, cold sweat, "lightness" in the head, apprehension of imminent fall and loss of consciousness. This variant dizziness systemic nature peculiar to lightheadedness and fainting different nature. When headedness often observed pallor, tachycardia, sweating, nausea, anxiety and blackout. The immediate cause of syncope - a decrease in cerebral blood flow below the level necessary to ensure that brain glucose and oxygen.

**Conclusions.** To achieve success in the treatment of vertigo requires an individual approach to each patient. Pathogenetic therapy of vertigo is the use of betahistine. The drug is effective in vertigo due to various etiologies dual mechanism of action: regulation of excitability of the vestibular nuclei and improves blood circulation in the vertebrobasilar basin and the inner ear. Oral solution Avertid, the production company "Ursell Pharma Ukraine" due to its high efficiency and low number of adverse events, as well as high compliance for patients can be recommended for medical use in the treatment of vertigo, including for long-term use.

**Key words:** dizziness, vestibular disorders, vertigo, Meniere's disease, vestibulology therapy, betahistine.

© Shponka I.S., Mnihovich M.V., Kyrylenko V.A., Merkulova D.O.

### **MORPHOGENESIS OF LIVER DAMAGE AND MORPHOLOGICAL GRADING THE DEGREE OF ACTIVITY AND STAGE OF DEVELOPMENT OF CHRONIC VIRAL HEPATITIS**

**Summary.** The article presents the main components of the morphogenesis of chronic viral hepatitis B and C, are considered invasive and non-invasive methods of diagnosis of liver fibrosis.

Clinical and laboratory diagnosis of viral hepatitis causes serious difficulties due to compensatory capacity of the liver and that dysfunction and appropriate clinical manifestation occur only in severe morphological changes of the body. Therefore morphologic diagnosis of liver disease should be early enough to recognize the disease before it we define ourselves characteristic clinical picture of chronic hepatitis or cirrhosis.

*Objective:* to study and according to the literature highlight the main features of morphological gradation level of activity and the stage of development of chronic viral hepatitis.

Viral damage universal reaction parenchymal liver cells is degeneration, necrosis of hepatocytes, and apoptotic cells hybel, which is a marker for cells Kaunsilmena. The second component morphogenesis - a cell infiltration (immune cell response to viral infection) associated with the migration and proliferation of T lymphocytes, forming aggregates in portal tracts with subsequent distribution in the parenchyma. The third component morphogenesis - liver fibrosis as a result of complex degenerative-proliferative responses in the dynamics of chronic viral infectious process [Pinzani et al., 2005].

**Key words:** chronic viral hepatitis B and C, liver biopsy, fibrosis, diagnostic methods.

© Starynets N.G.

## MODERN ASPECTS OF PSYCHOSOMATIC MEDICINE

**Introduction.** Psychosomatics is a modern clinical trend in medicine and medical psychology that studies the influence of psychological factors and their relationship with somatic processes. For the first time the ideas about relationship between somatic and psychic processes were expressed by Plato, Galen and Hippocrates who noted that strong emotional excitement could lead to disorders of physical functions and considered the disease as abnormal physical response to a stressful situation. The history of the current psychosomatic medicine begins with the psychoanalytic concept of S. Freud who explained the origin of symptoms imitating physical pathology by conversion mechanisms, that emerged as a result of the breakdown of psychological protection adaptation. The concept of current opinions is that any psychosomatic disease does not occur independently of either psychic or physiological peculiarities of an individual, only their interaction with the environment can lead to such state of a human body that is defined as a psychosomatic disease.

The dependence of the physical health of a person on his/her psyche is discussed by current clinicians who confirm the fact that a somatic disease as a process is also conditioned by psychological factors. Today based on this statement it is impossible to exclude the influence of emotional factors on any disease.

At present the psychosomatic medicine has gone beyond psychiatry; mostly this issue is discussed by doctors and scientists working in the field of psychiatry, psychology and some internists. The frequency of psychosomatic disorders is rather high and generally ranges from 15 to 50% on the whole, and from 30 to 57% in general medical practice.

Depressions of different severity dominate among psychosomatic disorders. An important distinguishing feature of depressions at the present stage is their excess beyond psychiatric care, continuous increase of neurotic or somatic forms as compared to classical endogenous depressions. At present the share of non-psychotic forms in the structure of the depressive pathology exceeds 60%.

Many scientists are interested in the problems of depressions in the general medical network. First of all this is due to wide prevalence of depressions among somatic diseases – according to different data their frequency ranges from 8 to 44%. In the general population depressive disorders occur in 5 to 17% of cases.

Exogenous depressions are observed in case of cardiac diseases, pathology of coronary and cerebral vascular systems. The depression immediately following myocardial infarction increases the risk threefold of the disease fatal outcome.

With the development of the psychosomatic medicine the question of the emotional impact on the etiology and clinical picture of diabetes appeared in the last century. It has been observed that patients with diabetes are more vulnerable to psychosomatic disabilities, especially depressive, than somatically healthy people.

Today stomach ulcer can be also regarded as a typical example of a psychosomatic disease when psycho-emotional and psycho-social factors play a significant role. Depressive disorders are observed in the patients with chronic renal insufficiency in up to 38% of cases, in dermatological practice in up to 52% of patients, and in patients with bronchial asthma in up to 32% cases.

Due to wide prevalence of depressive spectrum pathology and depressions it is recommended to widely implement the procedure of affective (depressive) disorder screening into the work of general medical institutions. The possibility of somatic projection of psychological factors should be considered by doctors-internists. Exactly a comprehensive approach to the study of acute and chronic pathological states is an important and in some cases - the only precondition to further improvement of the treatment process efficiency.

Thus, the origin of psychosomatic disorders should be considered within the framework of the current clinical medicine. Their timely detection and appropriate correction contributes to improvement of the psychic state and social-psychological adaptation of this cohort of patients.

**Key words:** psychosomatics, somatic pathology, affective disorders, depression.

© **Teklyuk S.V.**

Chair of Psychiatry and Addictology, Vinnytsia National Pirogov Memorial Medical University (56, Pirogov St., Vinnytsia, Ukraine, 21018)

## **APPROACH TO THE REHABILITATION OF PATIENTS WITH SCHIZOPHRENIA IN THE INITIAL STAGES OF DISEASE DEVELOPMENT**

According to the data of leading Ukrainian scientists, the growing influence of stress leads to an increase not only in the number of boundary spectrum of psychopathology, but also causes an earlier beginning of endogenous and malignant diseases, including schizophrenia. Actuality of development and introduction of effective methods of treatment and rehabilitation of patients with schizophrenia is caused, in particular with an early onset, high rates of disability and a suicide risk.

According to modern approaches to the problem of treating chronic mental illness rehabilitation must become the element in the overall structure of mental health care which is necessary for complex influence. In contrast to the narrowly directed care (only medicinal or only social), a complex approach has several advantages, as it at once affects all the aspects of life of patients and their close people. It enables to involve the remaining sides of patients' personality and to create on this basis a high enough level of motivation to positive changes, to form a conscientious attitude to treatment and responsibility for their behaviour.

Particular attention has recently been paid to the psycho-social rehabilitation of patients with the first episode of schizophrenia. It is proved that early detection and

timely medicamentous and psychosocial intervention improves the prognosis of the course of the disease after the first psychotic episode, minimizes negative social consequences for the patient and his environment.

Currently there is a wide choice of forms and methods of rehabilitation of patients, but the validity of their appointment and real effectiveness is often not taken into account. One reason for this is the lack of universally accepted criteria and objective assessment methods.

Thus it is apparent that the psycho-social rehabilitation of schizophrenic patients on the early stages of the disease is an actual problem of modern psychiatry and requires further search for ways and methods of its improvement and implementation into medical practice.

**Key words:** psycho-social rehabilitation, psychotherapy, schizophrenia, first psychotic episode.